

# LAPAROSCOPIC SURGERY FOR THE GENERAL SURGEON



**Dr Pravin Hector John**  
MBBS, MS, FIAGES, FALS, FIBC



**Dr John AC Thanakumar**  
MS, MNAMS, FRCS(Ed),  
FRCS(G), Dip MIS, FICS,  
FIAGES, FALS



**ANURAG HOSPITAL**

NO.8 KRISHNA NAGAR, SOWRIPALAYAM, COIMBATORE.

PH-8015087871/0422-7967544

Dear Friends,

I was pleased to learn about the Handbook on Laparoscopic surgery written by my colleague and friend Dr. John Thanakumar. This handbook should prove handy for postgraduate students and young residents beginning to get a feel of laparoscopic surgery early on in their careers. A handbook such as this one may be easier and more accessible to refer to for the basics of Laparoscopic surgery than a complete, bulky textbook on the subject. Laparoscopic surgery was novel to an earlier generation of surgeons most of whom had to learn on the job. An entire earlier generation of surgeon learned and refined their skills in laparoscopic surgery by a combination of intuition, hearsay and witnessing surgery at the occasional surgical workshop. Laparoscopic surgery is now firmly established as a modality of surgery in all surgical subspecialties. Our present generation of students, fellows and residents have access to a vast array of tools for training and learning Laparoscopic surgery. Dr. John Thanakumar possesses the perfect credentials to teach and train in laparoscopic surgery. He has over 30years of experience in laparoscopic surgery having his early surgical training in the academic environs of the United Kingdom. He has remained actively engaged academics at a national regional and international level.

I wish this handbook great success and popularity that it richly deserves.

Warm Regards



Dr. Pradeep Chowbey

MS, MNAMS, FRCS(London), FIMSA,FAIS, FICS, FACS, FIAGES, FALS, FAMS

Padmashri awarded by The President of India

Chairman - Max Institute of Laparoscopic, Endoscopic & Bariatric Surgery

Chairman - Surgery & Allied Surgical Specialities

Max Super-Speciality Hospital, Saket, New Delhi, India

Dear friends,

Greetings from IAGES Central Office.

It gives me immense pleasure to write a foreword to this masterpiece, crafted by Dr. John Thanakumar on ABC of laparoscopic surgery for the benefit of budding surgeons who are keen to learn the art and science of minimal access surgery.

Dr. John Thanakumar, IAGES Advisor and past President, has been a passionate teacher and trainer in the field of laparoscopic surgery. He has nearly 4 decades of surgical experience both in India and UK. His unquenchable thirst for academics is very admirable.

This 'Handbook of Laparoscopic surgery' has been well written with innumerable practical tips on various common topics in laparoscopic surgery.

This comprehensive concise book on MAS is the need of the hour and would be a great companion for the young surgeons. We are sure that it will soon find a place in the shelves of library in all teaching institution.

Wish you all 'Happy reading'

Affectionately yours



Dr.S.Easwaramoorthy

Prof of Surgery, Dept. of Surgery, Lotus hospital, Erode

IAGES President, 23- 24

MRCS Examiner, RCS Edinburgh

It is an honour for me to Forward the book 'LAPAROSCOPIC SURGERY FOR THE GENERAL SURGEON' written by Dr Pravin John and Dr John Thanakumar.

This book covers topics starting from History of Laparoscopy, Instrumentation, Ergonomics, Suturing, Knotting, Various common and advanced surgeries and most important a chapter on Complications of Laparoscopic Surgery which we all must be aware of and try to prevent as far as possible and should be prepared to detect and manage them effectively as and when they arise

Laparoscopic surgery has brought revolution in surgery in over last three decades and Dr John Thanakumar has been one of the pioneers. This book is compilation of practical tips which will be not useful for budding surgeons but established surgeons too. Each chapter covers details of Indications, Contraindications, Complications in a lucid presentation..

IAGES (Indian Association of Gastrintestinal Endoscopic Surgeons) is one the leading organisation in field of minimal invasive surgery and we have been conducting various courses including FIAGES and FALS. This book will act like a reference book especially for FIAGES candidates.

I would like to thank and congratulate Dr Pravin John and Dr John Thanakumar for taking up this academic venture of compiling a treasure of knowledge which will be beneficial for many postgraduates, young and established surgeons.

My best wishes on personal behalf and from IAGES



Dr.Sathish Midha

MS,FICS,FIAGES,EFIAGES, FAGIE,FAIS,FISG,FSGEI

CONSULTANT LAPAROSCOPIC SURGEON AND GI ENDOSCOPIST

VIVEKANAND HOSPITAL, RANCHI

midhasatish@gmail.com

+91-9835150204

Hony Secretary IAGES 2022-24

## **PREFACE**

The use of laparoscopy to remove gall bladder since the 1980s has opened up an enormous list of operations in the abdomen. The general surgeon deals mainly with abdominal conditions involving gallbladder, appendix, and hernias. Much of the ability to do other operations involve the principles of ergonomics, knotting and suturing at laparoscopy.

The book “Laparoscopic Surgery for the General Surgeon” is written to affirm the basic principles of laparoscopy and to encourage surgeons push the envelope to higher frontiers.

Hence these principles have been kept in writing this book. The young surgeon in training or in practice will do well to get the basics of laparoscopy well established in mind. With the practice of knotting and suturing in a continued fashion in endo-trainers, any level of mastery surgery in laparoscopic surgery can be obtained.

Pravin John & John Thanakumar



Dr Pravin Hector John  
MBBS, MS, FIAGES, FALS, FIBC  
Assistant Professor of Surgery,  
PSG Hospital, Coimbatore  
Email: [pravin.hector@gmail.com](mailto:pravin.hector@gmail.com) &



Dr John AC Thanakumar  
MS, MNAMS, FRCS(Ed), FRCS(G), Dip MIS, FICS, FIAGES, FALS  
President of IAGES 2012-14.  
Senior Advisor to IAGES  
Chairman & MD,  
ANURAG HOSPITAL,  
Coimbatore -641028  
Email: [drjact@gmail.com](mailto:drjact@gmail.com)  
Blog: [Lapsurgeon.blogspot.in](http://Lapsurgeon.blogspot.in)

## **Laparoscopic Surgery for the General Surgeon**

Chapter 1. History of Laparoscopic Surgery

Chapter 2. Instrumentation

Chapter 3. Accessing Peritoneum

Chapter 4. Laparoscopic Cholecystectomy

Chapter 5. Choledocholithiasis

Chapter 6. Laparoscopic Appendectomy

Chapter 7. Laparoscopic TAPP Repair of Groin Hernia repair.

Chapter 8. Laparoscopic TEP Repair of Hernia

Chapter 9. Laparoscopic e-TEP Repair of Hernia

Chapter 10. Laparoscopic Repair of Ventral Hernia

Chapter 11. Ergonomics

Chapter 12. Extra-corporeal Knotting

Chapter 13. Intracorporeal Suturing and Knotting

Chapter 14. Complications in Laparoscopic Surgery

## **CHAPTER 1: HISTORY OF LAPAROSCOPIC SURGERY**

“Diseases that harm call for treatments that harm less” William Osler

### **Introduction:**

The history of surgery dates back centuries. There have been defining moments in this long history such as the advent of anaesthesia, antisepsis, and antibiotics which have advanced the care of patients a great deal. Video laparoscopy is one such milestone which has had a great impact not only on surgeons but also on patients and the medical industry.

### **History:**

In 1901, George Kelling from Dresden, while at the University of Leipzig used a cystoscope to study the effects of pneumoperitoneum on the small bowel. In 1910, Swedish surgeon Hans Christian Jacobaeus of Stockholm did the first laparoscopy and thoracoscopy with a cystoscope and reported results in seventy-two patients.

The first surgeon from the USA to use laparoscopy was Bernheim of Johns Hopkins University Hospital. The first surgeon in Indian subcontinent to perform laparoscopically is Prof Udwardiya of Mumbai who is rightly called ‘The Father of Indian Laparoscopy’. The Trendelenburg position was advocated by Nordentoft to pass the laparoscope.

In 1920, Orndoff reported pyramidal trocars entering peritoneal cavity. In 1921, Goetze used the first manual insufflator. In 1924, Zollikofer used carbon dioxide instead of air with more safety. At this stage, the laparoscope was used to inspect the abdominal organs and the superiority of laparoscopy over exploratory laparotomy was described.

In 1933, Fervers described therapeutic laparoscopy by the use of laparoscopic adhesiolysis with diathermy. In 1936, Boesch of Switzerland described laparoscopic tubal sterilization.

Marked advances in imaging include the use of cold light by Forestier with fibreglass technology improving brightness with less heat. Another invention was the rod lens system by Hopkins in 1953 which consisted of the light carrying capacity giving plenty of applications to the laparoscope.



Kurt Semm from Germany wrote the first laparoscopic gynecologic atlas. He also improved the design of the automatic insufflator and performed the first laparoscopic appendectomy in 1983. Cuschieri and Baric used laparoscopy at this time for biopsies from liver.

The rigid split lens eyepiece helped another surgeon to be involved in the operation apart from the main surgeon. In 1985, charged coupled device (CCD), a three-chip camera dramatically catapulted diagnostic into a major therapeutic one. On 12 September 1985, Erich Muhe from Germany performed the first laparoscopic cholecystectomy. Philippe Mouret in Lyon, France repeated the performance in 1987 and made this procedure popular.

In the early 1990s laparoscopic cholecystectomy was fast becoming the first choice for the removal of the gall bladder. In 1991, Stoker removed a common bile duct stone with laparoscopy and left a T tube in place. Dallmagne in 1991 did the first laparoscopic Nissen fundoplication in Brussels, Belgium. Jacobs et al and Sclinkert separately reported the first laparoscopic colectomy in 1991. Laparoscopic gastrojejunostomy was first described in 1992 by Brune et al. Goh did the first laparoscopic Billroth II gastrectomy in 1992. In India the initial thoracoscopic mobilization of oesophageal carcinoma was carried out on 12 May, 1992, laparoscopic colectomy on 28 Nov 1992 and the laparoscopic abdominal perineal resection on 26 June 1993 by Dr John Thanakumar, et al in Coimbatore, India.

Ger did laparoscopic hernia repair in 1992 and Delaitre did the first laparoscopic splenectomy in 1992. Michael Gagnier did the laparoscopic Whipple's pancreatico-duodenectomy in 1992 as well as an adrenalectomy. The advent of bariatric surgery commenced in 1993 when Belachew and Legrand did the first lap band; and Clark and Wittgrove carried out the first laparoscopic gastric bypass.

This has been followed by surgeons from various disciplines of surgery such as urology, cardiac surgery and neurosurgery taking minimal access surgery to greater heights. With the liberal use of increasing indications, analogue cameras have given way to digital ones, halogen lights to xenon lights and the hand instruments have become more user-friendly. Generous use of endo staplers and ultrasound scalpels has made minimal access surgery easier and quicker.

**Table of Inventors and their contributions  
in MAS**

1901- Kelling – Peritoneoscopy  
1910-Hans Christian Jacobaeus-  
Thoracoscopy  
    Nordentoft- Trendelenburg Position  
1920 -Orndoff- Pyramidal trocar  
1921 -Goetze – Manual Insufflator  
1924 -Zollikofer- Carbon dioxide for space  
1933 -Fervers – First Adhesiolysis  
1936 -Boesch – Tubal Sterilization  
1953 – Hopkins - Rod lens system  
    Kurt Semm – Atlas in Gynecology  
    Kurt Semm – Automatic Insufflator  
1983.    Kurt Semm – Appendectomy  
1985- Erich Muhe – Cholecystectomy  
1987-**Philippe Mouret**–Cholecystectomy  
popularized  
    1991 – Stoker – Common Bile Duct Stone  
1991 – Dallmagne – Nissen Fundoplication  
1991 - Jacobs et al and Sclinkert –  
Colectomy  
    1992 - Brune et al – Gastro jejunostomy  
    1992 – Goh – Billroth II Gastrectomy  
    1992 – Delaitre – Splenectomy  
    1992 – Michael Gagnier – Adrenalectomy  
    1992 – Michael Gagnier – Whipple  
    1992 – Ger – Hernia  
    1993 – Belachew and Legrand – Lap band  
    1993 - Clark and Wittgrove- Gastric Bypass

## CHAPTER 2: INSTRUMENTATION

- Light Source
- Light Fiberoptic Cable
- Telescope
- Laparoscope
- Laparoscopic Camera System
- Video Signal Processor and Output

Imaging begins with the telescope and through the camera ends with the monitor. This includes the telescope, light cable, light source, camera head, camera processor, video cable and monitor.

### **Light Source:**

Most of the light sources use halogen bulbs, metal halide bulbs or xenon bulbs. Light sources help one to see the interior well. Halogen bulbs are 150 watts, metal halide bulbs are 250 watts and xenon bulbs are 300 watts. Bulbs wear out after some hours and this should be noted. Generally, metal halide bulbs last 250 hours and xenon bulbs last 500 hours. Caution must be exercised as the tip of the lighted laparoscope causes burns on the drapes or skin of the patient after 20-30 seconds of contact.

### **Light Fiberoptic Cable:**

To obtain a good picture, the fibre optic cable and the fibre bundle in the laparoscope should be adequate. If the picture on the monitor is dim after prolonged use of the light cable, a new fibre optic cable is changed in place of the old one. The old light cable should be discarded if the new image is excellent.

To identify a laparoscope with a broken light bundle, the surgeon sees the images as dark pictures; the dark pictures do not improve when the light cable or light source is changed. When the telescope is changed, then the picture quality improves remarkably.

## **Telescopes:**

The laparoscope helps the surgeon see the interior of the abdomen and hence forms the eye of the surgeon. The standard telescope is a 10 mm diameter scope with a 0-degree lens which helps visualization of the interior directly giving a panoramic view of the operating field. It is easy for the novice cameraperson to handle and the light is bright. This scope uses Hopkins rod-lens design. The newer scopes are of smaller diameter - 5 mm or 3 mm. Mini or micro laparoscopes have a 2 mm diameter; the recent design gives a good view of the field and bright images. These are useful not only for diagnostic purposes but also for advanced procedures. They in addition can be used in awake patients and at surgery, these can be interchanged with all the ports easily. The main setback is that they are damaged easily as they bend more readily.

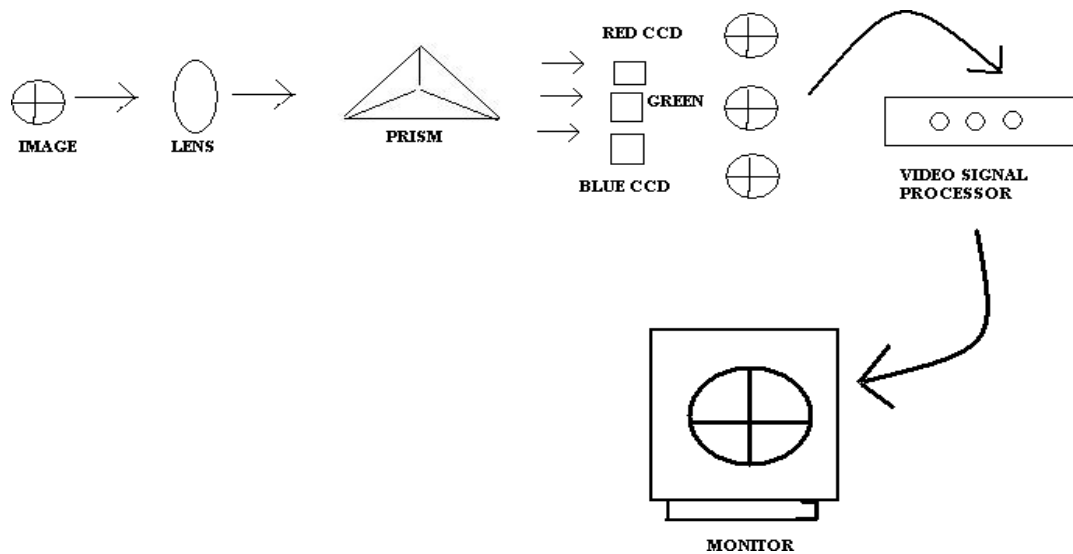
The angled telescopes 30 or even 45 degrees give more field of vision to the surgeon to achieve advanced surgery. Using these, the field of vision which is obscured by the distended bowel by the 0-degree telescope improves remarkably as the 30-degree telescope can look over anatomical barriers easily.

Advances in telescopes have led to digital telescopes where the telescope and the camera are integrated as one unit and the sensor is at the tip of the telescope; 'chip on stick' technology is useful, especially with a motorized tip which gives different angles for the surgeon to see. This however has the inability to focus especially at close ranges. The new generation of telescopes is autoclavable, especially with the camera systems. The three-dimensional (3D) telescopes offer depth to the field and are useful for suturing of tissues and dissection of tissues in advanced procedures. Robotic surgery involves the use of 3-D telescopes which by the depth of vision make surgery as fluent as open surgery and faster.

## **Laparoscopic Camera Systems:**

The camera head that attaches to the telescope using a coupler and the signal processing or camera control box is known as the camera system. At present cameras are single or three-chip systems. In a single-chip device, charge-coupled device (CCD) silicon consists of a grid of tiny image sensors known as "pixels". Better the pixels, the better the resolution of the picture seen by the surgeon. The single-chip camera has 550 lines of resolution whereas

three-chip cameras have more than 950 lines of resolution thus showing an image with far better resolution. In three-chip cameras, light enters the lens and is split into red, blue and green components by a prism allowing each colour band to fall on its specific CCD. Thus three-chip cameras provide the highest resolution and truest colour giving more than 950 lines of horizontal resolution.



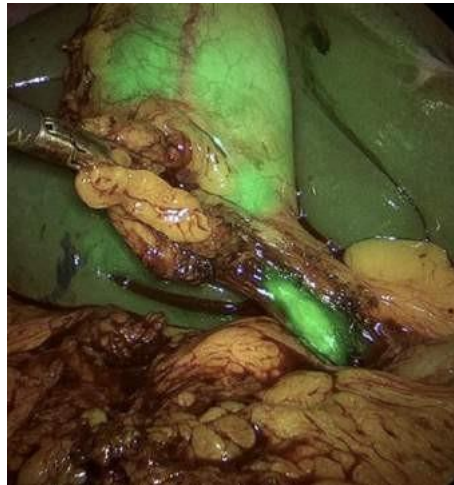
Three Dimensional camera systems never became popular though they were brought into the market in the 1990s. Surgeons needed to wear special glasses to see the image which gave depth to the field. This was thought to be useful in advanced laparoscopy, especially cardiac surgery. Due to added cost in the absence of data to suggest that these were really needed, they never became popular. However, the three-chip camera forms an integral part of robotic surgery.

The cameras can be of standard definition (SD) or high definition (HD). SD camera offers an image at the respect of 16:9 and with 640 horizontal and 480 vertical lines. Full HD camera offers an image at an aspect ratio of 16:9 and with 1920 horizontal and 1080 vertical lines giving more clarity to the surgeon than an SD camera

Full HD camera remains popular for advanced operative laparoscopy. 4K cameras and 8K cameras are now available in the market which offers far superior quality images. The video recording of the 4K and 8 K video images from the advanced camera systems consumes enormous space in the hard disc of the computer.



A new advance has been to use chemicals for a better imaging of the target organs. Using indocyanine green (ICG) imaging with high-definition cameras and sometimes with 3-D imaging with specific lenses and near-infrared (NIR) light, vascularity to the organs to the sutured anastomotic areas can be safely established in real-time surgery (3).



The outcomes of surgery can also be calculated with reasonable accuracy. The method appears to have more future applications in laparoscopy and video assisted thoracoscopy (VAT).

### **Medical monitor:**

The choice of the medical monitor depends on the quality of the laparoscopic camera used. Full HD camera uses 16:9 aspect ratio monitor and hence an inferior monitor projects images of inferior quality. So compatibility between the camera system and the monitor is vital to obtain great-quality images. Medical grade monitors are built to convey the operative picture with no time delay to the monitor. This maintains a continuous flow of surgery in real-time with no any loss of time from the surgeon to the viewer. In the less expensive commercial monitors used for entertainment purposes, there will be a delay between the actual event and the relay to the consumer. So commercial monitors are best avoided in surgery.

### **Video Signal Processor and Output:**

Outputs from the video signal processor can be analogue or digital. They are generally multiple outputs nowadays which carry the same intensity signal of the image to the video monitor, printer and digital tape recorder and capture devices. Three of the analogue output formats are composite, super video (Y/C) and RBG (red, green, blue). Composite signals have a single channel to carry information. Super video signals carry light and colour information on separate channels improving image and resolution. RBG signals are divided among four wires. These produce images of far better quality in resolution. These are most preferred.

There are many digital outputs also. The most common is DV output using IEEE1394

“Firewire” or “ i-link” output. DV output is a compressed format which must be uncompressed for viewing. Digital recorders have Firewire ports and record in tape formats such as DV and DVCAM. The final video can be exported to videotape, cd format, DVD format or web. To view analogue images on the computer, they need to be digitalized, rerecording the analogue images to a digital tape using computer bases analogue boards or capture cards.

## CHAPTER 3: ACCESSING PERITONEUM

- Veress needle
- Sites
- Trocars
- Anesthesia
- Difficult abdomens
- IA pressures
- Anatomy of umbilicus
- Methods:
  1. Closed method
  2. Open method
  3. Modified method
- Complications:
  - Bleeding from anterior abdominal wall
  - Perforation
  - Collapse
- Types of gas used

Pneumoperitoneum is essential to good laparoscopy. This gives good room for a view of the interior of the abdominal cavity. Once the surgeon sees well the expanded distance between the viscera and the abdominal wall, he is able to perform his surgery with ease. To achieve this, the Veress needle and insufflator are essential.



### **Veress Needle:**

Veress needle is made of metal with a hollow needle and sharp tip surrounded by a sheath mounted on a spring-loaded mechanism. The external metal sheath is threaded and screwed tight on the inner hollow needle. When fully assembled, the spring-loaded mechanism is tested and the tip of the interior which projects outside, when it comes into contact with the peritoneum retracts, exposing the sharp end to pierce the same. Once the peritoneal cavity is breached, the inner blunt needle comes out and protects against the viscera. Disposable Veress needles are also available.

The Veress needle is verified by checking the spring-loaded mechanism of the needle and then a syringe with saline is used to ensure that it is patent.

### **Carbon dioxide Insufflator:**

This essential piece of equipment is part of the trolley system which houses the entire laparoscopic set. The insufflator is switched on and the amount of CO<sub>2</sub> in the cylinder is verified to ensure a continuous supply for the entire procedure.

Insufflator is verified by keeping the tubing open and the flow rate at 6 L/min; the pressure reading via the open tubing should read 0 mm of Hg.

The flow rate is reduced to 1 L/min and the tube is kept kinked, then the pressure reading should indicate an obstruction and rise up to more than 30 mm Hg.

The usual reading of intra-abdominal pressure is 12 – 14 Hg mm of pressure which is safe for laparoscopy. This also gives adequate visualization of the viscera. Children need less intra-abdominal pressure of 6-8mm Hg. A high pneumoperitoneum affects the venous return of blood to the heart by pressing on the IVC which results in a fall in cardiac output.

### **Anatomy of Umbilicus:**

The position of the umbilicus is variable. In adults it usually lies between the xiphoid and symphysis pubis, lower in children and in persons with the pendulous abdomen, lying opposite to the disc between III and IV lumbar vertebrae. It forms the thinnest part of the abdominal wall due to embryology and hence is preferred by the minimal access surgeons for the insertion of primary access instruments.

In shapes, it may be inverted especially in young males and nulliparous women. It may be flat or convex in the obese, elderly and the ones with ascites. It may require cleaning with spirit and betadine to clear all debris.

Caution should be exercised in instances with umbilical hernia, with scars nearby which would indicate adhesions in close proximity below and with portal hypertension due to the presence of caput medusae. In malignant ascites, umbilicus may present Sister Joseph's nodule which could be biopsied at the time of laparoscopy.

Access to the abdomen using the umbilicus is sub-umbilical, supra-umbilical or transumbilical. The site is dictated by the type of surgery and the preference of the surgeon. For instance for laparoscopic cholecystectomy, appendectomy and gynaecological surgery, infra umbilical site of entry is popular. For laparoscopic hiatal surgery such as funduplications and Heller's procedure, the supra umbilical position of the primary site of access offers the advantage of better and closer visualization of the operation site. While doing TEP (transabdominal extraperitoneal) hernia repair for inguinal hernias, the surgeon uses an incision 1-2 cm below and lateral to the umbilicus. For doing laparoscopic lateral pancreatico-jejunal anastomosis, access sited 2 cm to the left lateral aspect of the umbilicus gives a good view of the site for suturing.

Though one should be familiar with the classical methods described, one should adopt his own technique and repeated access using the same method would make the surgeon proficient in that technique avoiding complications.

### **Methods of accessing the abdomen:**

There are 2 classical methods of accessing to the abdominal cavity and they are the closed method using a Veress needle and the open method using a Hasson cannula. We also describe our preferred third method of modified entry to the abdomen which offers advantages of the above two.

### **Closed Method :**

Generally, a sub-umbilical incision of 1 cm is made with the patient in the supine position. Trendelenburg's position of keeping the head end down helps to gravitate the abdominal viscera away from the pelvis. The Veress needle is verified for the intact spring-loaded mechanism and for the patency with saline. Holding the abdominal wall upwards and the needle at a 45-degree angle, it is passed into the peritoneal cavity. A clear 'give' is felt at the time of entry into the peritoneum as well as the hub confirms the spring-loaded entry of the tip into the peritoneal cavity. Saline loaded syringe helps to confirm the easy flow of saline and no return of the same on respiration. Bile on aspiration would indicate entry to the bowel and blood would denote the tip to be in blood vessels.

CO<sub>2</sub> is then connected to the Veress needle and pneumoperitoneum is commenced. At this stage of initial flow of CO<sub>2</sub> at the rate of 1 L / min should produce resonance on all four quadrants. If the intra-abdominal pressure is low and the four quadrants of the abdomen are resonant, then CO<sub>2</sub> flow may be increased to 4-5 L / minute till the intra-abdominal pressure reaches the setting of 12-14 mm of Hg.

The Veress needle is then removed and primary trochar is inserted via the same incision keeping the tip pointed towards the pelvis keeping it away from the aortic bifurcation. The position is verified by the insertion of the telescope to inspect the peritoneal cavity before connecting the CO<sub>2</sub> gas to the trochar. The rest of the trochars are inserted under the vision of the telescope.

### **Open Method:**

H M Hasson in 1971 described a trochar for open access to the abdomen. Hasson trochar consists of an outer cannula and an inner blunt trochar. Subfascial sutures secure the outer cannula and prevent the escape of CO<sub>2</sub> from the peritoneum.

The sub-umbilical incision is made. Linea Alba is incised and entry is made into peritoneal cavity. A finger inside the peritoneum safeguards the bowel. Hasson trochar is inserted and secured with a stay suture. CO<sub>2</sub> is then passed into the peritoneal cavity establishing pneumoperitoneum rapidly.

The disadvantages of this method are the long time taken and the escape of CO<sub>2</sub>. Vascular injury encountered by Veress needle entry is rare with Hasson's method, but the incidence of bowel injury varies from 4.8 to 9 per 10,000 cases.

Whatever the method employed, it is important that the surgeon uses his most familiar method for making the primary access. Practice makes perfect.

### **Modified Method:**

Our own method combines both the above techniques. A transumbilical incision is first made after cleaning the umbilicus and everting the same. The edges of the skin are held upwards with forceps and an incision is made vertically across the umbilical skin for a distance of 1 cm. A closed artery forceps is used to open the peritoneum and the interior of the peritoneal cavity is inspected. A 10 mm blunt trochar is inserted maintaining the traction on the umbilical skin upwards. The obturator is then removed, the telescope is passed in to confirm entry into the peritoneum and then CO<sub>2</sub> is insufflated.

This method has been used for more than 5000 cases. There is no vascular or bowel injury. However, it needs patience and practice.

### **Optical Access Trochars:**

Visiport (Autosuture) and Optiview (Ethicon) are two varieties of transparent trochars which have a groove in the centre of the trochar for maintaining a telescope. The rounded tip is transparent and it allows the passage of a curved knife blade to incise forwards whenever a trigger is pressed.

This trochar allows the passage of sharp, tight entry from the subcutaneous plane to the abdominal wall under the direct vision of the surgeon. Once the peritoneum is transgressed, CO<sub>2</sub> fills up the peritoneal cavity. Optical trochars when used carefully can also be directed to the retrorectus space as during an e-TEP for ventral hernia repair.

### **Threaded Trochar:**

A cannula with treaded exterior helps to avoid injury to the bowel. Due to the external threads, by rotating the cannula, the perpendicular force is converted to a screwing type of action while inserting the trochar. The treads help to spread the tissues and stretch them over the advancing tip.

A sub umbilical incision is made and the anterior rectus fascia; a laparoscope is placed in the cannula keeping 2 cm from the tip. By rotating the cannula over the anterior fascia, it is advanced into the interior. The threads allow the tissues to expand and allow the tip to progress forwards into the peritoneum. When the latter is breached, CO2 flow is commenced allowing the abdominal cavity to be lifted away from the viscera.

### **Hand Assisted Laparoscopic Surgery (HALS):**

Hand assisted laparoscopic surgery is useful in advanced surgery. In essence hand of either the surgeon or assistant is inserted into the peritoneal cavity to aid dissection. HALS is dealt in more detail elsewhere.

## CHAPTER 4: LAPAROSCOPIC CHOLECYSTECTOMY

- Introduction
- Indications
- Contraindications
- The technique of Laparoscopic Cholecystectomy
- Steps in Laparoscopic Cholecystectomy
- Difficult Laparoscopic Cholecystectomy
- Results
- Conversions
- Complications

### **Introduction:**

E Muhe of Boblingen, Germany carried out the first laparoscopic Cholecystectomy in 1985.

P. Mouret of Lyon, France described laparoscopic cholecystectomy in 1987 using cephaloid traction to the gall bladder. Subsequently, Reddick and Oslen in the USA followed up with an improvement of the same.

Dr Tehemton Erach Udawadia carried out the first laparoscopic cholecystectomy in India in May 1990. Since then, due to various factors such as marketing efforts by medical equipment companies, individuals, hospitals, and patients' preference for less painful procedures, laparoscopic cholecystectomy has caught on in India as well as the rest of the world. It has come to stay as the new "gold standard" therapy for symptomatic cholelithiasis. The excellent results from experienced centres have shown that laparoscopic cholecystectomy can be carried out safely not only in chronic but also in acute cholecystitis.

## **Indications:**

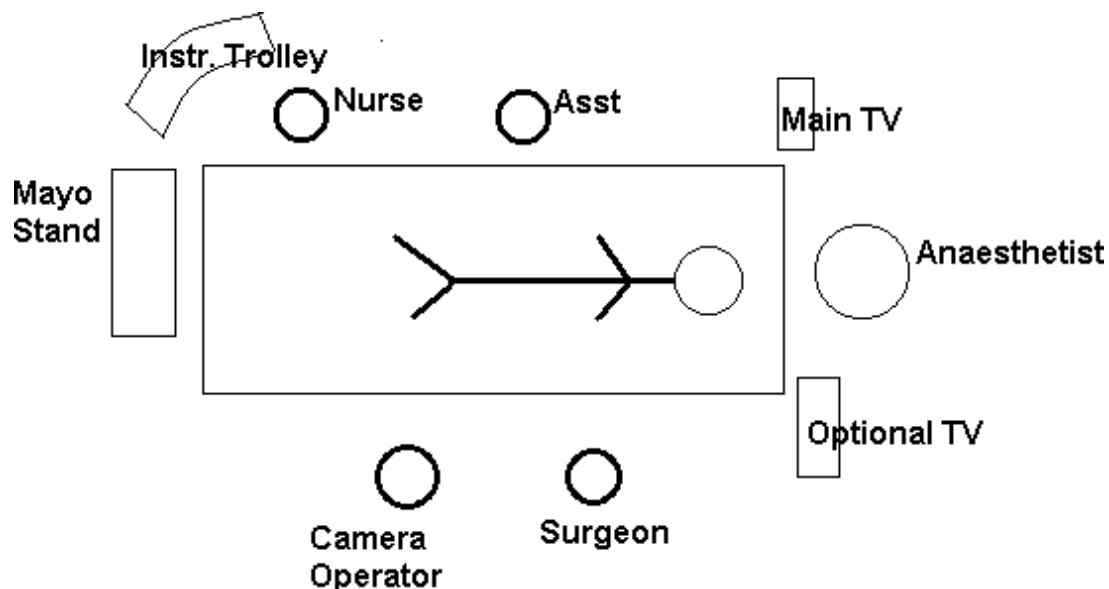
The skill to perform laparoscopic cholecystectomy should not expand the indications for surgery.

Patients should have symptoms attributed to documented gallstones. Occasionally patients with gallstones and no symptoms may be considered for surgery such as porcelain gall bladder, immunosuppression, lack of access to hospital care and diabetes mellitus. Patients with acalculous cholecystitis should be considered for surgery, especially with typical biliary symptoms and low contraction of gall bladder on biliary scintigraphy. In doubtful cases, upper GI contrast series, endoscopy, ultrasound, CT scanning & a cardiac evaluation may provide the true cause. Acute cholecystitis within 48 hours may be considered for surgery in experienced hands. Empyema and mucocele may make surgery difficult and long.

## **Contraindications:**

The only true contraindications for laparoscopic cholecystectomy are the inability to tolerate general anaesthesia and uncorrected coagulopathy. The so-called relative contraindications have not proved to be true contraindications with the passage of time and experience of the surgical team. These include empyemas, morbid obesity, cirrhosis with portal hypertension, previous major upper abdominal surgery, pregnancy and in suspected carcinoma gallbladder.

**Figure 1. Position of Patient:**

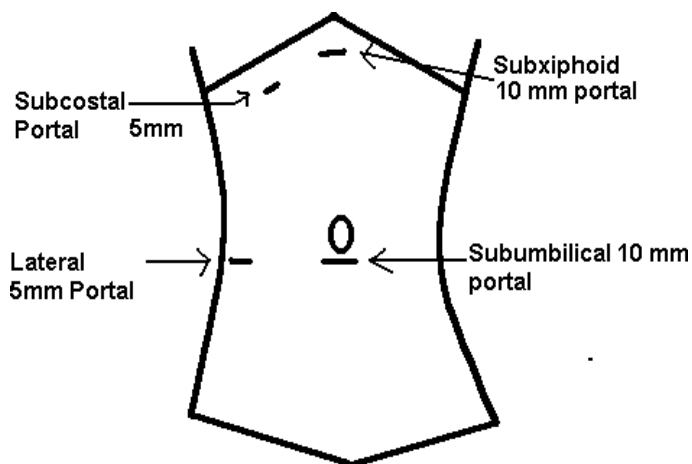


With the patient under general endotracheal anaesthesia, the antibiotic of choice is administered. The patient may need a nasogastric tube in acute cases with abdominal ileus. Whenever the bladder is distended above the level of the pubis, a urinary catheter may be required.

The position of the patient is supine with (figure 1) the surgeon on the left for cross access to the right upper abdomen. The camera operator is positioned to the left of the surgeon, with the assistant placed to the right of the patient. The European especially the French technique is to operate with the surgeon sitting or standing between the patient's legs kept in the lithotomy position. The first assistant stands to the right of the patient and the camera operator to the left.

### Technique:

After the introduction of pneumoperitoneum using either percutaneous or open (Hasson) technique using usually an infra umbilical incision, with the patient in Trendelenburg position, the viscera are inspected. The table is changed to a reverse Trendelenburg position with left tilt.





## Figure 2 Position of ports in Laparoscopic Cholecystectomy:

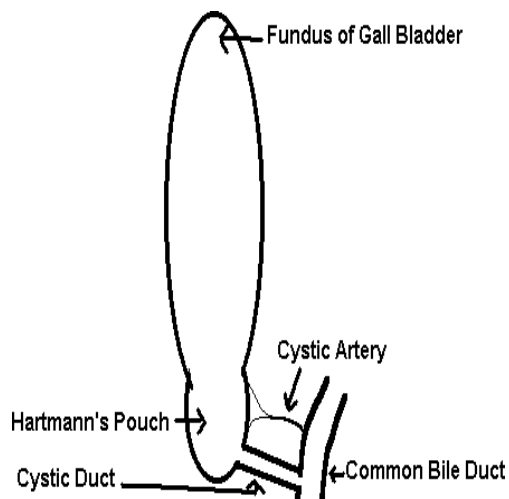
The epigastric trochar is inserted by making a 1 cm long incision situated 5 cm below the xiphoid process. The lateral 5 mm trochar is placed as laterally as possible in line with the umbilicus or below. Passing a grasper with a ratchet or spring device through the lateral trochar, the fundus of the gall bladder is held in a cephaloid and lateral direction. The epigastric trochar supports a 10 mm curved dissector (or 5 mm instrument with a reducer) and forms the main dissecting instrument. Adhesions present may be lysed and usually the Hartmann's pouch will be visualized.

A 5mm trochar is then passed in line with the Hartmann's pouch just below the right subcostal margin usually in the midclavicular line. This is used to hold Hartmann's pouch to aid in the dissection of Calot's triangle.

## Steps in Laparoscopic Cholecystectomy:

1. Infraumbilical trochar supports a 0 or 30-degree telescope.
2. The lateral trochar supports a grasper that holds the fundus of the gall bladder. This is held by the first assistant who applies traction in a cephaloid and lateral manner to retract the liver and open up to expose the body of the gall bladder and Hartmann's pouch.
3. If there are no dense adhesions, the entire gall bladder, cystic duct and porta hepatis can be seen (figure 3).

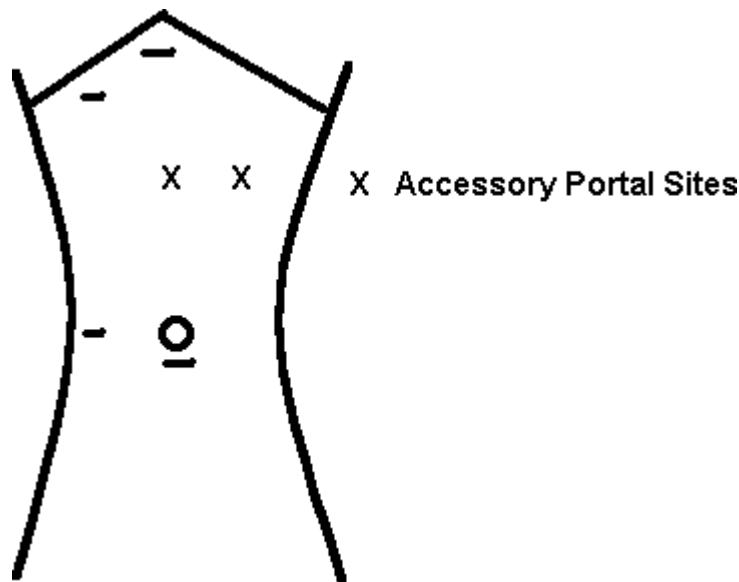
## Figure 3. Calot's triangle



The grasper passed through the medial port holds the Hartmann's pouch and by pushing it medially, exposes the back of the gall bladder and Hartmann's pouch; by pulling in laterally, it exposes the front of Hartmann's pouch, the cystic lymph node of Lund, the cystic artery and the front of the gall bladder.

4. Accessory ports may require to be placed depending on whether the visualization is adequate or not

**Figure 4. Sites for accessory ports in laparoscopic cholecystectomy.**



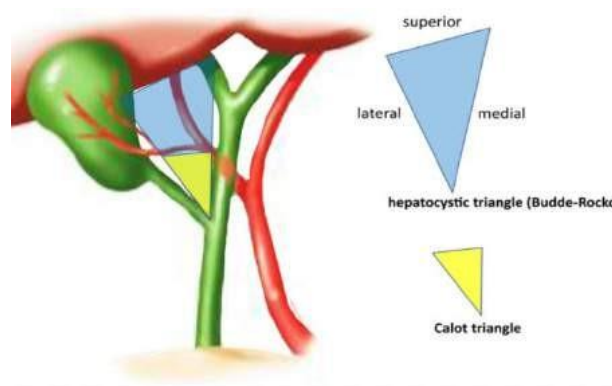
Accessory ports (figure 4) may be especially needed in acute cholecystitis, empyemas, distended colons and previous surgeries. The locations of the accessory ports are the midway between the umbilicus and epigastric port (A) or in the left subcostal (B) area usually mid-midclavicular line. A difficult visualization with 0-degree telescope may be improved by substituting it with a thirty-degree one.

5. Dissection is generally commenced in patients with few adhesions to the gall bladder, by releasing these from omentum, duodenum or hepatic flexure which are generally avascular. The dissection is away from the gall bladder towards the porta hepatis.
6. Dissection of Calot's triangle: The surgeon by using a two-handed technique with a curved rotatable dissector (Maryland) through the epigastric port and with a grasper through the subcostal port, holding the Hartmann's pouch, dissects the back of the pouch and the base of gall bladder by incising the peritoneum.

Then careful dissection is commenced at the anterior aspect of neck of gall bladder by incising the peritoneum to expose the Calot's triangle which comprises the cystic duct, hepatic duct and liver edge.

7. An enlarged cystic lymph node may obscure the blunt dissection. This lymph node of Lund generally denotes the proximity of cystic duct. Undue dissection proximal to the cystic lymph node may injure the common bile duct or the right hepatic duct. Diathermy is best avoided at this site.
8. The crucial part of dissection is to identify the junction of the infundibulum and the cystic duct by staying close to the gall bladder.
9. Dissection is carried distally to create a window between the body of the gall bladder and the liver bed and now the cystic duct is skeletonised. The window so created is widened till the gall bladder is attached at the fundus distally and the cystic duct and vessels proximally. The cystic artery may be visualized at this stage dividing into anterior and posterior branches.
10. The posterior surface of the gall bladder is exposed by applying traction with the forceps through the midclavicular trochar in an upward and medial direction (and fundal traction is superior). The back of the gall bladder is dissected in a similar manner.
11. Critical view of Strasberg has the following features (Fig 5):
  - The hepatocystic triangle is cleared of fat and fibrous tissue.
  - The lower one third of gallbladder is separated from the liver to expose the cystic plate.
  - Two and only two structures should be seen entering the gallbladder.

**Figure 5. Critical View of Strasberg**



12. After identifying the cystic duct and cystic artery separately and tracing them to their attachment to the gall bladder, they are double-clipped proximally and once distally with medium–large titanium clips. The clips on the cystic artery should lie on the main artery and not on anterior branch. A missed posterior branch can cause a troublesome haemorrhage later on. An operative cholangiogram may be contemplated now. Vicryl ties or absorbable clips may be used as an alternative.
13. The artery is divided first and the cystic duct afterwards between the proximal two and the single distal clips. Division of the duct initially may result in the avulsion of the blood vessel. No further dissection or unnecessary suction is carried out medial to the cut stumps which would result in the dislodgement of the same.
14. The grasper through the midclavicular trochar is repositioned to pull laterally and superiorly (and the fundal retraction superiorly). This exposes the anterior surface of the gall bladder. Dissection is carried out using a diathermy hook. Separating the gall bladder from its fossa is achieved by using a variety of instruments like the hook, blunt probe, scissors or irrigating cannula as per the surgeon's choice.
15. Dissection is carried out till a thin rim of liver tissue holds the gall bladder. Attention is turned downwards to the liver bed to verify the cystic vascular and biliary stumps. Haemostasis is verified and the gall bladder is finally detached from the liver.

16. The gall bladder is usually removed by using a specimen retrieval bag. This is achieved by using the epigastric or umbilical site. Sometimes the fascial opening may have to be dilated with artery forceps or cut with scissors to enlarge the opening and deliver a thickened gall bladder.
17. A drain is used in case of bile or stone spillage after due washout with saline.
18. Following gall bladder removal, the CO<sub>2</sub> is expelled and 10 mm port incision is closed with fascial absorbable sutures and external skin sutures. 5 mm port incisions do not require deep sutures.

### **Difficult Laparoscopic Cholecystectomy:**

#### **1. Previous Operations:**

Previous surgical scars may predict intra – abdominal adhesions. Hence either Hasson's open Technique of primary trochar insertion or a smaller telescope such as a 3 mm or 5 mm one may be used to create a pneumoperitoneum. After visualization of the peritoneal adhesions, these adhesions may be Released before making further ports.

#### **2. Gall bladder:**

A thickened small fibrosed gall bladder seen on ultrasound may predict a difficult operation. The junction of the cystic duct to the infundibulum may not be clearly apparent.

A tense enlarged gall bladder may be due to a stone blocking the cystic duct. The gall bladder may be difficult to hold because of its turgidity. Percutaneous partial aspiration of the gall bladder improves the handling remarkably. Complete aspiration makes it difficult to separate the gall bladder from the liver bed. Dense vascular adhesions of the gall bladder to the omentum, transverse colon and duodenum encountered in acute cholecystitis and empyemas may require careful dissection and cutting. No ductal or vascular structure

Should be divided prior to a clear demonstration of anatomy. A suction cannula with irrigation in difficult cases may help during dissection.

### **3. Cystic duct:**

Cystic duct anatomy especially at the main ductal system varies.

Stone in the cystic duct may be milked up toward the gall bladder prior to the application of endo-clips and division.

The short cystic duct will necessitate a clear demonstration its junction to the common bile duct so as not to damage it. A tie using Vicryl intra or extracorporeal technique is most useful in addition to an endo-clips  
Undue pull at the Hartmann's pouch should always be avoided while using end-oclips to avoid tenting and damaging the common bile duct.

An inflamed cystic duct may also be treated as above. If the cystic duct is torn and a stump is seen, a tie with an endo-loop is easier. If the stump is too short, a suture using a needle with 3-0 Vicryl may be required if an experienced team is operating; otherwise open conversion. Aberrant bile ducts may be present and require clips prior to division.

### **4. Cystic artery:**

The cystic artery should be divided prior to the cystic duct to prevent avulsion injuries.

Cystic artery anomalies need to be recognized. A magnified view of the artery should be differentiated from the right hepatic artery. In cases of doubt, dissection of the artery is carried on to show its branches on to the wall of the gall bladder.

Cystic artery bleed may be encountered due to the division of the posterior branch after clipping the anterior branch. It is vital not to panic and apply clips desperately in puddles of blood. Pressure with

An unremoved gall bladder may control the bleed when arrangements for suction and irrigation, are made. Get a fresh gauze piece inside.

After a few minutes of using suction and irrigation, the bleeder is identified and clipped safely or diathermised under vision. A further difficulty in achieving haemostasis requires open conversion.

## **5. Gall bladder perforation:**

This occurs especially in inflamed organs. A tear in gall bladder if small, may be controlled with endo-clip or endo-loop tie. Peritoneum should be irrigated with sterile fluid.

Dropped stones should be removed as far as possible. Small stones may be sucked using 10 mm cannulae.

Large stones may require removal with claw forceps or a retrieval bag along with the gall bladder. Usually dropped stones or bile spillage shows no major complications during follow-up.

However occasionally intra-abdominal abscesses and a persistent draining sinus tract have been reported communicating with a small gallstone.

## **6. Specimen retrieval:**

The gall bladder if it presents difficulty in delivery would need aspiration of bile and evacuation of stones. Further difficulty necessitates the incision at the port site to be widened. Umbilical delivery of specimens may be an easier alternative in view of no muscles. A thickened gall bladder may be bagged in a retrieval bag before delivery.

## **7. Drainage:**

Routine drainage to the peritoneal cavity after a straightforward laparoscopic cholecystectomy is not necessary. The indications for peritoneal drainage catheters are:

- i) bile spillage
- ii) persistent bile leakage
- iii) bleeding from the liver bed
- iv) acute cholecystitis
- v) empyemas
- vi) a difficult laparoscopic cholecystectomy.

The closed system of drainage is the usual method. A 5 mm grasping forceps is passed from the substernal or the midclavicular port into the lateral port. The lateral port is removed with part of these forceps projecting outside the skin. A catheter is then inserted in from lateral forceps which is then guided to the liver bed.

Among gall stones, cholesterol stones are composed mainly of cholesterol, black pigment stones are due to bilirubin pigment, and brown pigment stones are made up of a mix of pigment and bile lipids. CBD stones may be symptomatic or silent being discovered by accident during routine investigations.

The incidence rate for gallstones is 10-20%. Approximately 600,000 cholecystectomies are performed in the United States every year, and choledocholithiasis complicates 10-15% of these cases.

In the tropics, intestinal helminthiasis may complicate CBD stones by increased infections and sometimes may contribute to the formation of the same. Ascariasis and Clonorchis can migrate into the CBD from the duodenum and can promote bile stasis and infection and stones. CBD stones are more common in women.

This personal method has been found to be useful to connect most brands of Indian catheters to be used for closed drainage with the easily available urobags in India.

### **Conversion to open operation:**

The surgeon should not hesitate to convert from laparoscopic to open surgery in case of unclear anatomy or unexpected problem at the surgery.

The indications for conversions should be clear and they are:

- i) Unclear anatomy
- ii) Uncontrolled bleeding
- iii) Suspected injury to viscera or bile duct
- iv) Unexpected pathology is not amendable to laparoscopic management viz. resectable carcinoma.
- v) Common bile duct stone that cannot be removed laparoscopically with no chance of subsequent endoscopic removal (Billroth II anastomosis, duodenal diverticulum, previous failed ERCP)
- vi) When there is no progress in surgery. This may vary up to 30 minutes or even an hour.



## Results of Laparoscopic Cholecystectomy

STUDY Biliary Inj	PTS	Convert	Mortality	Maj	Compl
The Southern Surgeons Club 0.5	1518	4.7	0.07		1.5
Cuschieri et al 0.3	1236	3.6	0.00		1.6
Soper et al 0.2	618	2.9	0.00		1.6
Spaw et al 0.0	500	1.8	0.00		1.0
Wolfe et al 0.0	381	3.0	0.09		3.4
Bailey et al 0.3	375	5.0	0.03		0.6
Graves et al 0.3	304	6.9	0.00		0.7
Peters et al 0.4	283	2.8	0.00		2.1
Schirmer et al 0.7	152	8.5	0.00		4.0

### Complications:

Mortality after this procedure is rare, usually due to unrelated causes. However, death may be due to bile duct or intestinal injury. The conversion rate varies from 1.8 to 8.5 % and is usually greater in the early part of the surgeons' experience. Major complications such as bile duct injuries are rare.

This has achieved the status of 'gold standard operation'.

## **CHAPTER 5: COMMON BILE DUCT (CBD) STONES**

Common bile duct stones are common. Choledocholithiasis makes the diagnosis and management of gallstones difficult and adds morbidity. Management of choledocholithiasis has varied in different centres of the world. The expertise available in the centre locally is most helpful in the decision of endoscopic, open surgical or laparoscopic route of management.

Choledocholithiasis may be the result of either the primary formation of stone in the CBD or the passage of gallstones from the gallbladder through the cystic duct into the CBD. There are many factors which add to the formation of bile stones. They are stasis of bile, infection, the altered chemical composition of bile, sludge in the bile and increased destruction of red blood corpuscles.

10% of all gall stones have CBD stones and hence the surgeon needs to be aware of the management of these stones.

Diagnostic modalities include clinical and investigations. Charcoal's triad - intermittent fever, pain and jaundice may be indicative of underlying cholangitis with stones. Altered liver function tests may be indicative of biliary stasis (1).

Ultrasound and CT scanning are frequently done. CT scan is more accurate of CBD pathology than ultrasound which may have the overlying gas masking the CBD with pathology. The sensitivity and specificity of US and CB are 76 % and 98 % respectively.

Magnetic Resonance cholangiopancreatography (MRCP) is a useful diagnostic facility and the images are similar to those obtained by direct cholangiographic techniques. MRCP shows remarkably high sensitivity (81-100%) and specificity (85-100%). False positives however can be obtained in those with air bubbles or surgical clips near CBD.

### **Endoscopic Management of CBD stones:**

ERCP (endoscopic Retrograde Cholangio Pancreaticography) originally described by Classen and Demling and by Kawai remains popular (2). A long-side viewing endoscope is passed. Catheters with radio-opaque tips are passed into the ampulla of Vater. Selective catheterisation of the CBD is done to avoid the entry to the pancreatic duct via the papilla. A sphincterotome is passed after confirmation of anatomy, a sphincterotomy is necessary for many situations. 85-90% of stones can be removed by balloon catheters or Dormia baskets.

Complications include haemorrhage, perforation, cholangitis and pancreatitis. The morbidity and mortality is 6.5% and 1% respectively in experienced centres. 75% - 80% of complications can be managed without surgery.

#### Operative Cholangiography (IOC):

Mirizzi developed operative cholangiography in 1931 with the idea to improve on 50% rate of negative CBD explorations and 25% of retained stones in those who underwent CBD explorations.

IOC once used routinely is now used electively only in a few cases. Abnormal findings at IOC are dilated CBD of more than 1 cm, filling defects in CBD, dilated intrahepatic biliary ducts, absence of free flow of dye into the duodenum and absence of dye back into the common hepatic duct.

Recently intraoperative ERCP has been tried with some success along with laparoscopic cholecystectomy using CO<sub>2</sub> for insufflation. The duodenojejunal junction has to be occluded to prevent distension of the small bowel to ensure smooth cholecystectomy along with endoscopic CBD stone removal.

In 1993, DePaula et al advocated laparoscopic antegrade transcystic sphincterotomy, along with laparoscopic cholecystectomy and laparoscopic CBD exploration.

In failed post-surgical cases of stones in selected cases, interventional radiologists attempt percutaneous transhepatic cholangioscopy and retrieval of proximal stones in the biliary tree and do flushing for the sediment in the CBD.

Operative CBD exploration consists of transcystic CBD exploration (3) and CBDE (exploration). In small undilated CBD with multiple stones situated in the lower part of the duct, transcystic exploration of CBD can be done by passing a catheter via the cystic duct, cholangiogram, flushing and balloons. Where the CBD is larger such as 1 cm or more, the CBD at laparoscopy be opened - CBDE- and the stones can be removed directly from it. Following this, a T tube can be left in the CBD to decompress it and for post-operative cholangiogram. Where the surgeon is sure that there are no residual stones in the CBD through the table choledochoscopy and preoperative cholangiography, the CBD can be primarily closed.

### **Conclusion:**

ERCP removal of stones has become safe management for CBD stones in elective cases prior to laparoscopic cholecystectomy for gall stones. However, in selected cases of CBD stones, the other methods of stone retrieval as described may be considered.

### **References:**

- 1) John R Craig and Aaron S Fink. Endoscopic management of CBD stones. *Laparoscopic Surgery of the abdomen*, 2004; 161-168
- 2) Fink A. Current dilemma in the management of CBD Stones. *Surg Endosc.* 1993;7:285-291.
- 3) Hunter J, Soper N. Laparoscopic management of bile duct stones. *Surg coin N Am* 1992;72:1077-1097.

## CHAPTER 6: LAPAROSCOPIC APPENDECTOMY

- Indications
- Technique
- Our Preferred Method
- Complications
- Popularity
- Safety and feasibility
- Efficacy
- Special techniques
- Recommendations

### **Indications:**

Laparoscopic appendectomy has become popular due to not only diagnosing but also ruling out causes of abdominal pain, especially in women other than appendicitis. Women can have an ectopic pregnancy, torsion of ovarian and para-ovarian cysts, degeneration of myomas, etc which can mimic appendicitis a great deal.

Laparoscopic appendectomy is an easy way to diagnose the cause to be acute appendicitis and also treat it at the same time. Laparoscopy is easy, quick and accurate. Patients prefer to stay in the hospital for a day or so and they also want to return to work in the shortest time possible. In most cases, it can be completed within 45 minutes.

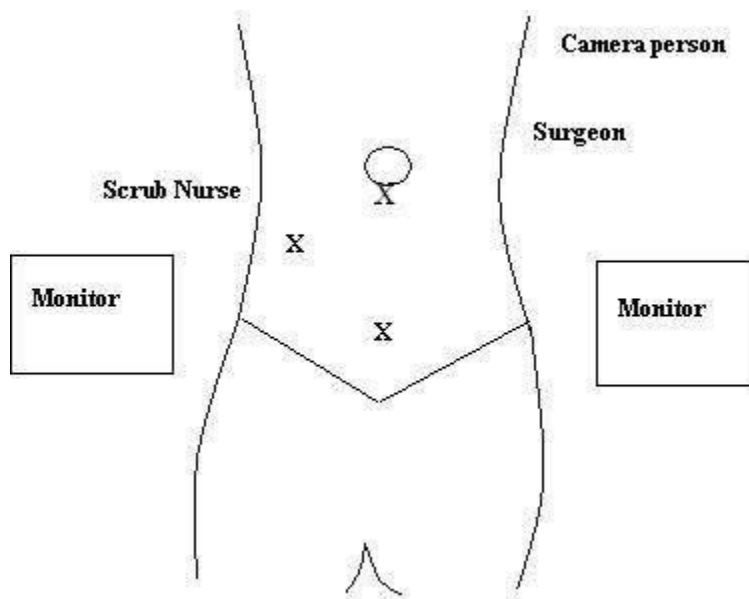
It has been proven this procedure remains invaluable in patients with undiagnosed abdominal pain of the right iliac fossa requiring further diagnostic intra-abdominal exploration as well as patients with perforated appendicitis with or without an intra-abdominal abscess.

This technique truly makes appendectomy a daycare procedure. Patients can resume a diet within a few hours after laparoscopic appendectomy and in most cases can be discharged within 24 to 36 hours.

## **Technique:**

Room Setup: The surgeon stands on the left side of the patient and the scrub nurse assistant is on the right side. Two monitors are kept adjacent to the hip of the patient.

**Fig 1. Picture of Port Placement:**



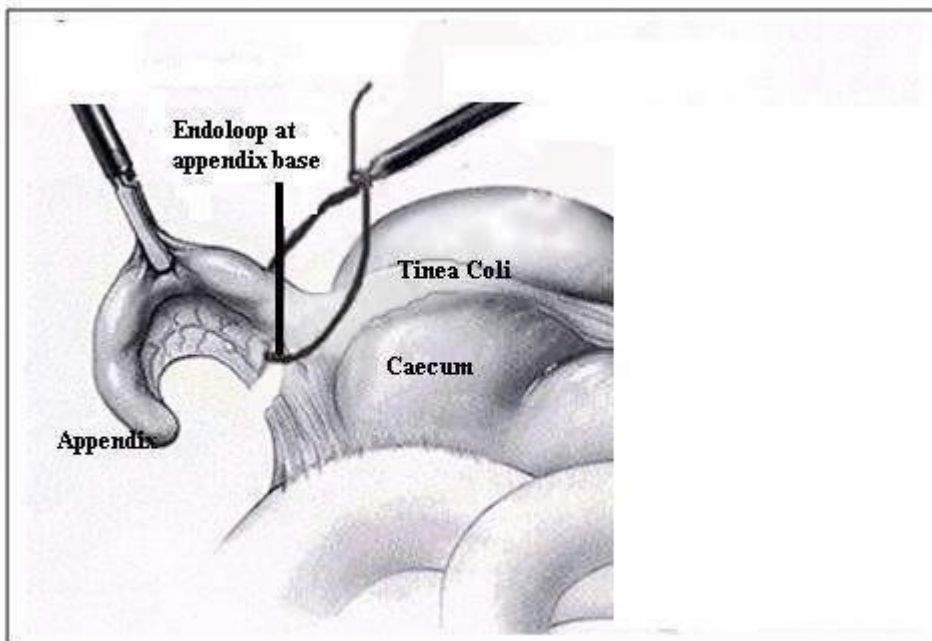
Telescope is inserted via the umbilical or infra-umbilical trochar usually using a 10mm telescope. Two 5 mm access ports in right lumbar and hypogastrium respectively.

The Position: The patient is in the supine position, left arm kept by the side of the patient and the right arm kept at right angles for blood pressure monitoring and intravenous access (Fig 1). The surgeon stands on the left side of the patient towards the cranial side with the cameraman to the right looking towards the right iliac fossa at the monitor kept in line against the right hip. The scrub nurse is to the right of the patient and uses the monitor to the left of the patient.

A pneumoperitoneum is obtained in the usual fashion. Three trocars are inserted. One trocar 10- mm (Umbilical) and two 5 mm (Right Upper Quadrant and Suprapubic).

While the grasper via the right iliac fossa is used for holding the appendix, the dissector through the suprapubic port is used for dissection and energy sources. The caecum is retracted upward toward the liver. In most cases, this manoeuvre will bring into view the base of the appendix and then the rest of the retrocecal appendix into view. The appendix is held with a 5 mm grasper inserted via the RIF trocar.

**Fig 2. Endo-loop for appendectomy**



A Maryland dissector is used to create a mesenteric window behind the base of the appendix. The window should be made as close as possible to the base of the appendix and it should be 1cm in size.

Using bipolar diathermy, the meso appendix which carries with it the appendicular artery and also the accessory appendicular artery (near the base of appendix), is divided carefully avoiding contact with the caecum. The division is kept as close to the appendix as possible. The appendix is now held only as a finger-like structure. A preformed endo-loop is passed around

it and the noose is brought to the base at the junction of the appendix with the caecum (Fig 2). After ensuring adequate tightness of the knot, the appendicular base is divided after passing another endo loop to tie a knot about 1 cm from the more proximal knot. It is then ligated at its base and cut. The base of the appendix is inspected for haemostasis.

The inflamed appendix is then collected in an endo bag and removed via the suprapubic port. This ensures that the specimen does not come into contact with the incision site. The intra-abdominal cavity may be irrigated with copious amounts of normal saline as dictated by the operative findings.

Drain is not necessary as a routine after an inflamed appendix is removed.

### **Our Preferred Method:**

Our method of choice would be the transumbilical route for the camera port. We visualize the base of the appendix and identify the junction of the base of the appendix with the caecum. We dissect the mesoappendix at the base with Maryland forceps and create a window. A 2-0 silk tie measuring 4 inches is passed through the defect and brought around the base of the appendix. Using intracorporeal means this silk is tied around the base of the appendix at its junction with the caecum. Only one tie is tied towards the caecum.

Now attention is turned to the mesoappendix which is divided close at its junction to the appendix with bipolar diathermy or ultrasound scalpel. Both these energy forms do not pass the current to the base of the caecum. Care should be taken to avoid contact of the hot instrument with the large bowel to prevent delayed necrosis.

Once the division of the mesoappendix is complete, the appendix is held at the base with the grasper and divided distal to the silk tie. The specimen is then bagged and removed via the suprapubic port. We feel that this tie is similar to the one used at open surgery and hence is strong.



## **Complications:**

1. Finding mass at surgery: At times, one finds an appendicular mass. At this stage, a decision is made after initial dissection to mobilize the appendix. If it can be removed safely, then that would be the best option. If the appendix cannot be removed safely, then the abdomen is closed to prevent damage to the bowel and after 3 weeks or later the patient can be re-explored.

2. Appendix not visualized: Uncommonly the surgeon is humbled by the fact that the appendix is not visualized at all due to numerous bowel adhesions at this site. This generally means that the appendix is inflamed and may be retro caecal. Painstaking dissection is required to sight and remove the appendix. If not, open conversion is the best option. On rare occasions, appendix may be in the left iliac fossa; the liver on the left would suggest this.

3. Appendicular abscess

4. Appendicular perforation

5. Bleeding from appendicular vessels

6. Carcinoma of caecum

7. Normal appendix

8. Postoperative infection: Postoperative Sepsis: Intra-abdominal Lavage with large amounts of normal saline after suction of all the purulent material at the end of the procedure appears to have decreased the number of postoperative septic episodes or postoperative intra-abdominal abscesses. However, several patients were readmitted to the hospital with severe abdominal pain and sepsis within ten days after this procedure. Using an endo bag to collect the specimen also serves to decrease the post-operative infection of the wound.

9. Appendix cannot be found

10. Slipping of ligation/clips on artery

11. Delayed Perforation of Bowel due to the injudicious use of heat sources

12. Interloop abscess

13. Post-operative abscess formation elsewhere in the abdomen.

### **Popularity:**

Laparoscopic appendectomy is a procedure which has rapidly matured in the early nineties due to the introduction of the ENDO GIA instruments. Although some authors have criticized this technique for its cost, there is no doubt this procedure will become the standard of care in patients with acute appendicitis and undiagnosed RLQ pain.

### **Safety and Feasibility:**

- Confirmed to be safe.
- Longer time depending on the surgeon's experience.
- Post-op complications are not statistically higher than open appendectomy.
- Safe for perforated appendix –but intra-abdominal abscess should be monitored.
- Safe in children.

### **Efficacy:**

- Improves the diagnosis of RIF pain in women and children.
- Meta-analyses have confirmed that key advantages of wound infection (by 60% )
- Faster postoperative recovery (35 %) – allows an early return to normal activities.
- Reduction in post-op pain.
- Reduction in the hospital stay.
- Cosmesis superior- especially with the small trocars
- Less post-op adhesions.

### **Special Techniques:**

- Basic technique uses three ports.
- Convert if the appendix cannot be found.
- No need to remove the appendix at the diagnostic laparoscopy.
- Bipolar coagulation is the preferred
- Lasers and staples are not cost-effective.
- Ultrasonic make laparoscopic appendectomy safer and easier.
- The base of the appendix is healthy with one/two endo-loops
- Metal clips alone are not recommended
- Appendix transected about 5mm from the distal ligature
- It is not necessary to bury the stump.
- Remove the appendix via the port, or if big in pouch.
- Peritoneal washout if abdominal contamination

### **Recommendations:**

- Diagnostic laparoscopy especially in patients where diagnosis is unclear.
- If appendix normal, search for other pathology.
- In absence of pathology - remove the appendix.
- It is feasible in patients with uncomplicated acute appendicitis.
- It is feasible in patients with complicated appendectomy, with the expert surgeon.

## **CHAPTER 7: LAPAROSCOPIC TAPP REPAIR OF GROIN HERNIA**

### **LAPAROSCOPIC TRANS-ABDOMINAL PREPERITONEAL HERNIA REPAIR (TAPP)**

“ That which is new at this time will one day be ancient;

As what is ancient was once new.

It is not the length of time which gives value to things,

It is their own excellency “-Augustine Belloste, 1645-1730.

Laparoscopic inguinal hernia repair is an accepted method of treatment for inguinal hernia which is a common surgical condition. The main indications are bilateral hernias, recurrence after open surgery and the patient's preference for laparoscopy. A summary of the laparoscopic transabdominal preperitoneal repair (TAPP) for inguinal hernia is outlined here with the advantages and disadvantages.

#### **Introduction:**

Since the advent of laparoscopic cholecystectomy, many operations have followed suit. Laparoscopic hernia repair is now one of most sought-after operations by surgeons and patients alike. There are mainly two routes namely transabdominal preperitoneal (TAPP) and totally extraperitoneal (TEP). TAPP was used at the initial stage and this gave way to TEP repairs.

Prior to embarking on the laparoscopic TAPP, it is wise to review the National Institute for Clinical Excellence (NICE) guidelines issued to the NHS in England and Wales on the use of laparoscopic surgery of hernia.

Patients should be fully informed of all the risks and benefits of open and laparoscopic surgery by either the transabdominal preperitoneal (TAPP) or total extraperitoneal (TEP) approach, to enable them to choose between procedures. In particular, the surgeon should consider discussing with the

patient the individual's suitability for general anaesthesia, the nature of the presenting hernia (that is, primary repair, recurrent hernia or bilateral hernia), the suitability of the particular hernia for a laparoscopic or an open approach and the experience of the surgeon in the three techniques.

In the TAPP procedure, the repair is performed by inserting instruments through the abdominal wall and through the peritoneum.

A mesh is inserted and the peritoneum is covered over it.

In the totally extraperitoneal (TEP) method, the hernia is repaired without entering the peritoneal cavity. This approach is recent and more difficult to do, but there may be less risk of damaging organs in the abdomen.

A discussion of possible seroma occurrence 2 weeks after surgery can be discussed with the patient at this stage.

### **The technique of surgery:**

Anaesthesia is usually general anaesthesia, but regional anaesthesia has also been described in some centres. Patients with no significant co-morbid disease can be admitted in the morning of surgery in the fasting stage. At the time of induction of anaesthesia, a single dose of intravenous prophylactic antibiotics is administered.

### **Position:**

Position of the patient is supine with both arms by the side tucked carefully away from the metal parts of the table. A urinary catheter is required during the surgery if there is any doubt of residual urine in the bladder. Monitors generally two in number, are placed at the bottom of the table. The surgeon stands at the head end of the patient if the suturing is contemplated. Surgeon if he chooses the endo hernia stapler, can stand on the opposite side of the hernia for instance on the right-hand side for a left hernia and on left hand side for the right hernia. The camera person stands on the same side of the surgeon behind him and the scrub nurse stands on opposite side of the surgeon. Usually, there is need for an assistant in TAPP.

### **Initial access:**

Instillation of the pneumoperitoneum may be done in many ways, but commonly with the veress needle using the umbilical or sub-umbilical route followed by a 10 mm trocar entry for 30-degree telescope. On the other hand, using a Hassan cannula, an open technique can be used to enter the peritoneal cavity. It is important to adopt the policy of careful entry of initial blind trochar by any familiar means to avoid damage to the bowel, vessels or other viscera. Two accessory trochars –left and right, are inserted under vision in the middle of the spino umbilical line staying lateral to the inferior epigastric vessels. Varying degrees of Trendelenburg tilt may be required to gravitate the bowel away from the operating area.

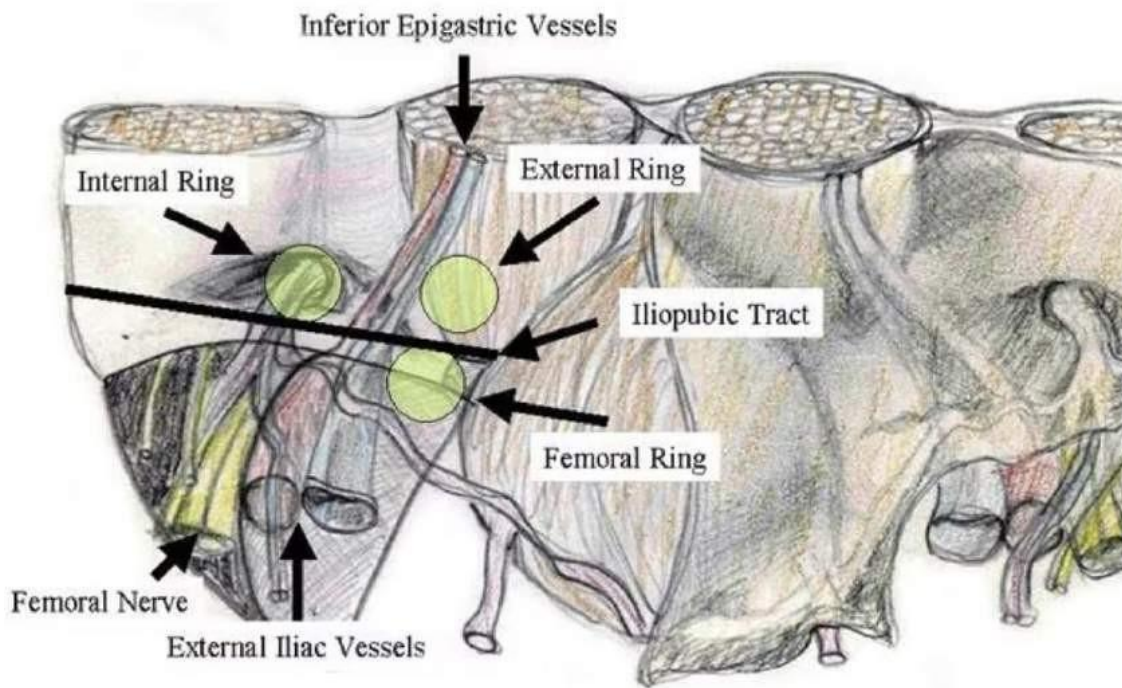
### **Landmarks:**

TAPP is generally easier than the TEP method to identify landmarks. The main landmarks to look for, using both external pressure and the visual interior are the pubic tubercle, ilio pubic tract, the bladder in the midline and the bowel on the lower aspect of the field.

The parietal peritoneum is folded into three distinct entities. The three folds in the anterior peritoneum are clearly identified. Median umbilical fold is solitary, midline and is the remnant allantois side. They contain the obliterated umbilical artery. The lateral umbilical folds on the most lateral aspect contain the inferior epigastric vessels.

Hernia is identified as a defect in the parietal peritoneum. If the defect is found lateral to the inferior epigastric vessels in the lateral umbilical fold, it is an indirect inguinal hernia. If the defect is medial to the vessels, it is a direct inguinal hernia. Pantaloon hernia consists of both direct and indirect hernias. A femoral hernia is diagnosed by the sac medial to the femoral vein. An obturator hernia is made out as an outpouching of the peritoneum through the obturator foramen.(figure 1)

**Fig 1. Inguinal anatomy**

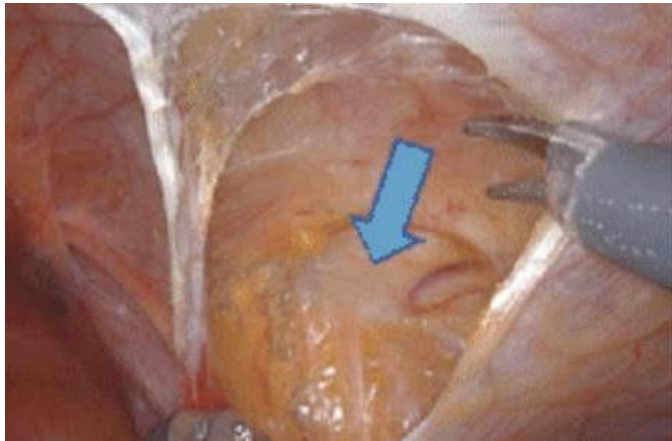


Inguinal anatomy from laparoscopic viewpoint.

**Dissection of sac:**

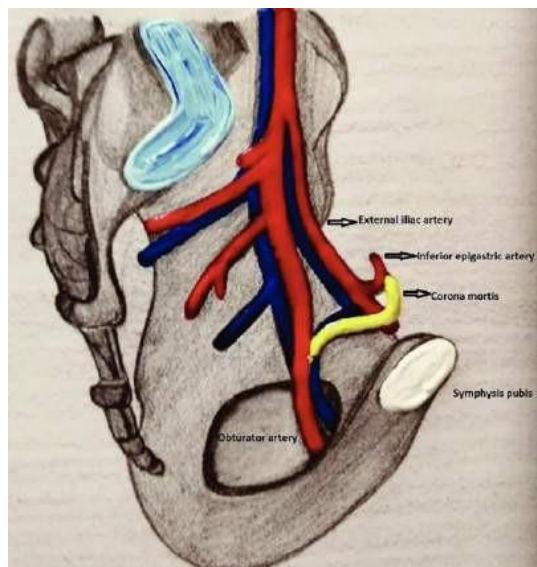
As soon as the landmarks are made out and the hernia sac is seen, an incision is made on the parietal peritoneum 2 cm above the hernia defect starting laterally from the anterior superior iliac spine to the medial umbilical ligament, (figure.2) taking care to avoid the inferior epigastric vessels.

**Fig 2 Peritoneal Incision**



This flap of the peritoneum requires usually nothing more than endo scissors dissection occasionally with a touch of monopolar diathermy (alternatives are bipolar coagulation and ultra-sonic scalpel dissection). A plane is opened along the transversalis fascia anterior to the peritoneum exposing the conjoint tendon laterally the cooper's ligament medially and the ilio pubic ligament inferiorly. Care is taken to avoid excessive bleeding from corona mortis (figure.3) which is due to the vascular anastomosis behind the pubis.

**Fig 3. Corona mortis**

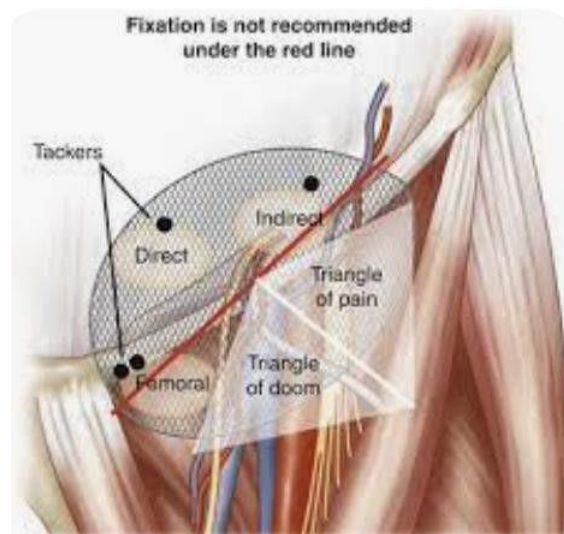




The medial extent of the dissection should be across the midline to the opposite side. Lateral extent should be the region of the anterior superior iliac spine. The posterior extent of dissection should include separation of the peritoneum from the vas and cremasteric plexus and testicular artery in the males and the round ligament in the females on the medial side; and the psoas muscles laterally. The upper flap usually does not require any separate dissection.

Carefully the triangle of doom and the triangle of pain (figure 4) are identified and the structures therein are avoided. They are both anatomically known as quadrangle of disaster.

**Fig 4. Triangles of Doom and Pain**



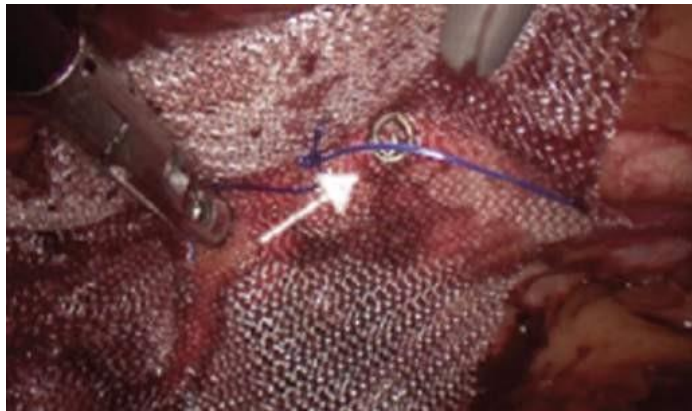
### **Deployment of mesh:**

When the sac of the hernia is reduced fully, a polypropylene mesh fashioned to 15 x 12 cm size is rolled like a cigarette and inserted into the peritoneal cavity using the camera port. A single stitch in the middle of the mesh helps to align the centre of the mesh to the internal rings. This helps the mesh to cover laterally the internal rings (and the indirect hernia defect), medically the direct hernia component down to the femoral and obturator hernias. This

method is so lacking in open surgery. The mesh is unfolded to roll outwards and downwards so that all the regions of the hernia mentioned vide supra are adequately covered. The corners of the mesh should lie flat without folding against the parieties and inferiorly the mesh should lie comfortably anterior to the bladder.

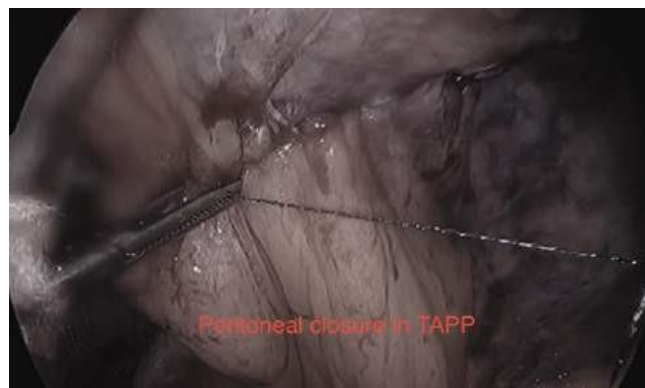The mesh is secured by using usually two endo-tacks (figure 5) in the region of Cooper's ligament.

**Fig 5. Endo-tack fixation**



First tack fixes the mesh to the parieties and second endo-tack prevents rotation of the mesh. If the hernia defect is large, then more tacks may be required. Intra corporeal sutures or fibrin glue may also be used instead of tacks for the fixation of mesh. The peritoneum is then closed over the mesh (figure 6) with continuous 2-0 prolene sutures.

**Fig 6. Peritoneal Closure**



### **Closure:**

After verifying hemostasis, the trochar is removed after evacuating the carbon dioxide. The 10 mm trochar is closed with a fascial suture. The 5 mm trochar sites may be covered with steri-strips. Urinary catheter is to be removed on the table.

### **Caution:**

There are steps which may involve specific dangers in laparoscopy.

- During the initial dissection of the peritoneal flap, care is taken to pull the peritoneum inwards with the left-handed forceps to avoid damage to the inferior epigastric vessels.
- During the dissection of the lower flap, avoid entering the bladder.
- Laterally, the three names nerves ilio inguinal nerve, the genital branch of genitofemoral nerve and the lateral cutaneous nerve of thigh should be left alone without much dissection to prevent neuralgia.
- Identification of the angle of doom is of paramount importance to avoid fatal bleeding.
- The corners of the mesh should be opened well and should not roll up along with the peritoneum which would increase the recurrence of the hernia.
- While closing the peritoneum over the mesh, all parts of the mesh should be covered to prevent adhesions of the bowel to the mesh.

Post-operative care:

The patient is made to sit up in bed after recovery, to have sips of fluids the same afternoon and should be on a normal diet if there is no nausea. The patient should be encouraged to walk up to the toilet to pass urine and is generally discharged in 24 hours. The patient is advised to drive a car if there is no pain after 4 days and can undertake sedentary jobs. Our patient review is within 14 days unless there is any evidence of fever, swelling or pain.

## **Complications:**

### **Haemorrhage**

Though minor bruising near port sites does not cause any problems to the patient major abdominal wall bruising requires observation as an inpatient. This is largely to the damage to the lateral port insertion into branches of the inferior epigastric vessels. Preventive steps include appropriate identification of the lateral umbilical ligament with the inferior epigastric vessels and transillumination of the abdominal wall with the light from the telescope.

Scrotal hematomas are due to inappropriate dissection of the distal part of the sac in the complete hernias. In moderately large hernias where the apex of the sac enters the scrotum, it is useful to tie off the proximal part with an intracorporeal tie, divide and leave the distal sac in situ.

### **Visceral damage:**

Injury to the blood vessels can be avoided during initial entry by open technique. Injury to the bowel occurs more frequently in re-operations and can be avoided using optical trochars for initial entry to the abdomen.

### **Seromas:**

Seromas occur in the inguino-scrotal area after surgery in about 11% of patients. fortunately, pre-operative counseling about this event helps to allay the anxiety of the patient. Once the seroma occurs after 2 weeks, it takes around 2-3 months to settle down. Preventive steps include on the inversion of the sac in large hernias and fixation with a suture onto Cooper's ligament or the pubis and tight supportive underwear. Inappropriate aspiration of the hematoma results in reaccumulation of the fluid, haemorrhage and infection.

### **Inguinodynia:**

Laparoscopic repair and tension-free repair at open surgery have much less recurrence compared to Bassini and Shouldice approach. Inguinodynia otherwise known as chronic significant posternioplasty pain seems to vary between 6% to 31% of the cases. Postoperative pain may be due to adhesions of the ilio inguinal to the mesh, the use of tacks, the sutures and the type of mesh. The exact reason for the pain remains elusive. Lightweight meshes cause less stiffness. Fibrin glue and absorbable tacks are being used nowadays to fix the mesh to the surrounding tissues to decrease the incidence of pain.

### **Small bowel obstruction:**

The mesh should be fully covered by the complete suturing of the peritoneum. Otherwise the bowel can get stuck to the mesh and create intestinal obstruction. Large gaps in the defective closure of the peritoneum can encourage migration of the intestines and obstruction.

### **Port hernias:**

Port hernias can be minimized by the use of disposable ports, pyramidal tips, trochars with dilating tips and linear blades. All the 10 mm trochar sites require a fascial suture to prevent herniation.

### **Urinary retention**

Early ambulation and patient nursing methods help to decrease the post-operative retention of urine in most cases. Bladder injuries during surgery are avoided by ensuring the patient has fully voided prior to anaesthesia or by insertion of the catheter is needed under anaesthesia.

### **Recurrence**

Recurrences are due to faulty techniques in most cases. Ensure that the mesh covers an area of 4-5 cm all around the hernial defect to avoid recurrence. Too small a mesh, rolled up edges, and not covering the main sites of herniation and hematomas are the usual factors at the surgery.

Avoiding straining and post-operative cough and the correct choice of the patient for surgery is helpful in avoiding recurrence.

### **ADVANTAGES OF LAPAROSCOPIC HERNIA REPAIR**

If carried out by experienced teams, laparoscopic hernia are quick to perform both in one-sided and bilateral sites compared to open. The patient has less pain, less scarring and return to normal activity is earlier . Laparoscopy using TAPP also identifies asymptomatic hernia on the contralateral side in about 10% of cases easily. TAPP hernia is useful when the hernial sac descends into the scrotum and is moderately large.

### **DISCUSSION**

Ger techniques of laparoscopic hernia repair were first in 1990 with just as simple a mesh plug in the defect. Presently, two types of laparoscopic hernia repair; the trasabdominal pre-peritoneal (TAPP)repair and the totally extraperitoneal (TEP) repair are in vogue. The TEP may offer some advantages over the TAPP in terms of post-operative pain and reduced potential for intraperitoneal complications, but with a higher learning curve. TAPP repairs are technically easier, provide clearer anatomy and do not demand excessive instrumentation as compared to the usual laparoscopic armamentarium.

However, surgeons need to evolve a higher level of technical skill to perform laparoscopic hernia repairs. Long term results are awaited and there is refinement of the technique still going on, For these reasons laparoscopic hernia repairs are not universally adopted. However, recurrence rates are very low when compared with both the open and laparoscopic mesh repairs with randomized studies showing no difference between the two. The size of the mesh should be large enough to prevent recurrences. A distinct disadvantage of laparoscopic repair is the increased cost. Laparoscopic route is of particular use in bilateral hernias and recurrences after open surgery.

## **Summary :**

Since 1992 the TAPP hernia repair has become safe and effective operation, simpler to perform compared to TEP repairs. With the increasing level of skill and experience in hernia surgery, this technique and TEP may become more acceptable in future. Complications of laparoscopic repair have to be addressed and the learning curve acknowledged.

## **Bibliography:**

1. Ger R, Monroe K, Duvivier R. Management of indirect inguinal hernias by laparoscopic closure of the neck of the sac. *Am J Surg* 1990;159:370-3
2. S.A. Kapisiris, W.A. Brough, C.M.S Royston, C.O'Boyle and P.C. Sedman. Laparoscopic transabdominal preperitoneal (TAPP) hernia repair-A-7-year two center experience in 3017 patients: *Journal of surgical Endoscopy*, Volume 15, Number 9/ September, 2001.
3. Wellwood J, Sculpher MJ, Stoker D, et al. Randomised controlled trial of laparoscopic versus open hernia repair for inguinal hernia: outcome and cost. *Br Med J* 1998;317: 103-10
4. Millikan KW, Kosik ML, Doolas A. A prospective comparison of transabdominal preperitoneal laparoscopic hernia repair versus traditional open hernia repair in a university setting. *Surg Laparosc Endosc* 1994;4:247-53
5. Brooks DC. A prospective comparison of laparoscopic and tension-free open herniorrhaphy. *Arch Surg* 1994;129:361-6
6. Stoker DL, Spiegelhalter DJ, Singh R, Wellwood JM. Laparoscopic versus open inguinal hernia repair: randomised prospective trial. *Lancet* 1994;343:1243-5
7. Kiruparan P, Pettit SH. Prospective audit of 200 patients undergoing laparoscopic inguinal hernia repair with follow-up from 1 to 4 years. *JR Coll Surg Edin* 1998;43:13-6

8. Khoury N. A comparative study of laparoscopic extraperitoneal and transabdominal preperitoneal herniorrhaphy. *J Laparoendosc Surg* 1995;5:349-55
9. Liem MS, van Steensel CJ, Boelhouwer RU, Clevers GJ, Meijer WS, Vente LS, van inguinal hernia repair. *A, J Surg* 1996;171:281-5
10. Seid AS, Amos E. Entrapment neuropathy in laparoscopic herniorrhaphy. *SurgEndoc* 1994;8:1050-3
11. Wilson MS, Deans GT, Brough WA. Prospective trial comparing Lichtenstein with laparoscopic tension-free mesh repair of inguinal hernia. *Br J surg* 1995;82:274-7
12. Payne JH, Grininger LM, Izawa MT, Podoll EF, Lindahl PJ, Balfour J. Laparoscopic or open inguinal herniorrhaphy? *Arch Surg* 1994;129:973-9



## Chapter 8: LAPAROSCOPIC TEP REPAIR OF GROIN HERNIA

### Introduction

The common laparoscopic techniques for groin hernia repair are transabdominal preperitoneal (TAPP) repair and totally extraperitoneal (TEP) repair. In TAPP the operating surgeon enters the peritoneal cavity and repairs with a mesh through a peritoneal incision over possible groin hernia sites. TEP varies in that the peritoneal cavity is not violated and mesh is used to cover the hernia defect from outside the peritoneum. This approach is generally more difficult than TAPP but may have fewer complications as access into peritoneum is not required. Laparoscopic repair is in general considered more difficult than open repair. TEP hernia was first described by Duluq in 1991(1).

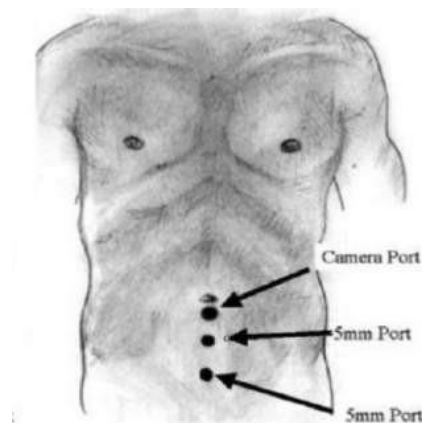
### Indications

TEP repair can be chosen in unilateral or bilateral cases primarily or recurrent cases after open hernia repairs.

### Contraindications

The patient needs to be fit for general anaesthesia to undergo TEP repair. The one who is unfit for general anaesthesia for medical reasons is not fit for TEP repair.

Large scrotal incarcerated hernias can be difficult to do using the TEP method, but possible in experienced hands with a urinary catheter in situ.



In acute situations of strangulation, a TEP hernia is best avoided as the bowel cannot be visualised for viability at the surgery. However opening of the hernial sac can be done in situations to visualise or reduce the interior, but the opening has to be closed carefully to prevent fistulation of the mesh (2).

Preperitoneal previous surgery such as prostate or bladder tumours or radiotherapy can produce dense adhesions and increase the urological complications of TEP(3). These have to be weighed in carefully before choosing an open or laparoscopic route for groin hernia surgery.

### **The technique of Laparoscopic TEP**

The patient is advised to void just before surgery and a urinary catheter is not always required. If it is a recurrent hernia or a large-sized hernia, an indwelling catheter minimises bladder injury and hence is most useful.

### **Steps in TEP**

General anaesthesia is required. If regional analgesia is used, an inadvertent pneumoperitoneum may create increased pain during the surgery and hence is usually avoided.

The patient is in a supine position with arms by the side and monitors at the foot end of the patient. The surgeon the nurse with the camera person stands on the contralateral side of the hernia. In a bilateral hernia, the surgeon stands on one side first to complete the hernia and the team switches over to the other side of the operating table for the other hernia.

The ipsilateral incision is made just below the umbilicus just lateral to the midline measuring more than 1 cm. The incision is extended to the anterior rectus sheath to expose the rectus muscle. The muscle fibres are separated with small S-shaped retractors to visualise the posterior rectus sheath.

Stay sutures are taken on both sides of the divided anterior rectus sheath to anchor the Hasson canal which is then inserted in the retro-rectus plane. The areolar avascular tissue is identified, CO2 inflow is started and tunnelling is commenced.

Tunnelling is done with a 0-degree telescope by to and fro movements in the midline. Tunnelling can also be done with a specialised balloon Trocar. The exchange to 30-degree telescope at this stage is done to facilitate better visualisation.

The pubic bone in the midline is identified as a white structure. Lateral dissection reveals the public tubercle and the Cooper's ligament. A direct inguinal hernia may be encountered at this site. The transversalis fascia otherwise known here as pseudo sac can be separated gently and the hernia is reduced to identify the Hasselbacch's triangle. The triangle is bounded by pecten-pubis below the inferior epigastric vessels laterally and the lateral border of the rectus muscle medially,

The femoral hernia has the sac into the femoral ring entering below and the inguinal ligament medially. When the femoral hernia is reduced, the external iliac vein is seen laterally with the lacunar ligament medially.

Inferior epigastric vessels are seen on the roof, situated medial and above the deep inguinal ring through which the spermatic cord structures in males and the round ligament in females enter. This is the site of an indirect inguinal hernia. The sac of an indirect hernia may be shallow and can be reduced easily from the cord. Where it is large and complete by entering the scrotum, it is gently separated from the vas and cremasteric vessels, and divided as high as possible. The proximal end of the sac is secured with an endo-loop or a suture to ensure no exposure of viscera to the mesh. The distal end of the divided sac is cauterised and left open without suturing to establish drainage.

Parietalization of the cord is separating the vas deference till it curves medially defines the posterior extent of dissection. Laterally the psoas major muscle is exposed with the deeper nerves protected by the areolar tissues. Medially dissection is carried out beyond the midline.

15 x 12 cm rolled polypropylene mesh is inserted with a central tie and used to cover the hernial defect. A mesh conforming to around this size is the norm but may vary on the size of the defect. The mesh may be secured with sutures, staples or glue. Larger hernial defects require fixation of the mesh to Cooper's ligament to prevent recurrences. Large hernias also need the pseudo sacs to be reduced and fixed to the rectus muscles or Cooper's ligament to minimise serums.

With carefully controlled insufflation of CO<sub>2</sub>, the mesh is held in place and the anterior rectus sheath is closed under vision, Sub-culticular sutures for the wound margins with local anaesthetic infiltration complete the operation.

### **Difficulties during TEP**

1. Creation of a retro muscular plane can be difficult initially. Thin retractors, good lighting directly from above, as well as a relaxed patient help with the development of the correct plane for the initial trocar. Gas leak is prevented by the insertion of a wet gauze into the wound alongside the trocar and secured with a stitch.
2. Bleeding from the corona mortis is avoided by not rubbing the pubic bones injudiciously. Bipolar vessels are useful to secure venous ooze along with local pressure. Bleeding from the inferior epigastric vessels can be best avoided by early control. These vessels are left on the roof side of the dissection and should not be dissected to hang loosely from above.
3. Penumoperitoneum inadvertently due to small tears in the peritoneum will mar the dissection. Sometimes it is inevitable. A Veress needle in Palmer's point usually helps to deflate the peritoneal cavity enough to continue with TEP. Any significant tear of the peritoneum should be closed carefully especially if it is placed adjacent to the mesh. The viscera mainly the bowel can cause adhesions to the mesh and can result in fistulation and mesh sepsis at a later date apart from intestinal obstruction.
4. Hernia sacs can be large and complete in indirect hernias of long duration and need careful meticulous dissection. Hernial sacs of the direct hernia if they appear fatty and vascular, are likely to have a urinary bladder or diverticulum of the bladder in the elderly and are best treated by an indwelling catheter on the table.
5. Angle of Doom and Quadrangle of pain are not so named without a reason. These should be remembered during careful, meticulous dissection with attention to detail. Prevention of disasters should be the aim.
6. Local constant pressure in the operated site for a few weeks after surgery in the form of a truss can be considered in the elderly, and recurrent and debilitated patients to prevent seroma.

## **References:**

1. Vandana Soni. Totally extraperitoneal repair of Groin hernia (TEP). Comprehensive Laparoscopic Surgery 4th Ed;177-185.
2. Tammy Kindel and Dimitry Oleynikov. Laparoscopic Total Extra-Peritoneal (TEP) Inguinal Hernia Repair. Hernia Surgery 2016.; 461-466.
3. Dulucq JL, Wintringer P, Mahajna A. Totally extraperitoneal (TEP) hernia repair after radical prostatectomy or previous lower abdominal surgery: is it safe? A prospective study. Surg Endosc. 2006;20(3):473–6.

## **Chapter 9- EXTENDED VIEW TOTALLY EXTRAPERITONEAL - eTEP – REPAIR**

### **Laparoscopic Totally Extra-peritoneal Repair of Groin Hernia (TEP)**

#### **Introduction**

The main theoretical advantage of TEP is that it does not invade the peritoneal cavity doing away with enteric perforations or vascular disasters. The extraperitoneal route is based on the well-established Rives-Stoppa technique.

TEP is more difficult to learn as the space is restricted and the closer ports are not conducive to suturing the mesh. Surgical trainees find it more difficult to learn TEP compared to TAPP method of repair.

In 2012, Jorge Daes described the extended view of TEP known as e-TEP method of repair (1).

e-TEP is different from TEP in the following aspects:

1. Quick and easy extraperitoneal space
2. Larger surgical area to visualize and operate
3. The non-rigid placement of ports makes it easy in varied situations
4. Easy parietalization of the cord structures
5. In large inguinoscrotal hernias, easy management of the distal sac
6. Easy management of pneumoperitoneum which can occur not infrequently (2)

## **Indications**

It is easier than TEP to master. Nearly 80% of surgeons adopt the e-TEP technique in their practices once they are exposed to it.

It is useful in obese and post-bariatric patients.

It is useful where the umbilicus is low and the distance between the umbilicus and the pubis is short. In TEP, the placement of ports will be closer and more cumbersome.

It is useful in previous pelvic surgeries.

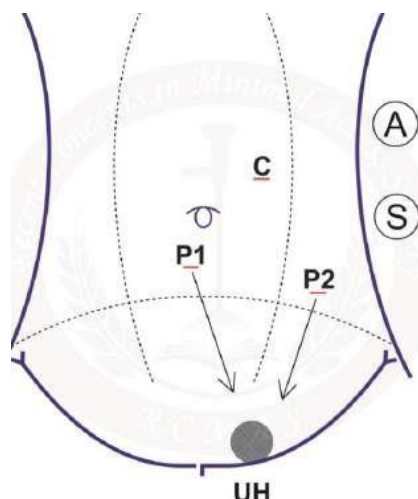
It may be considered in sliding, large hernias or even incarcerated hernias, but a 5 mm intraperitoneal port needs to be inserted to assess the viability of the bowel.

Main differences between e-TEP compared to TEP repair methodology

In unilateral hernias, the primary 10 mm trocar is placed about 5 cm above the umbilicus and 4 cm lateral to the midline on the ipsilateral side. This forms the camera port and the initial port for making the tunnelling.

Where there is previous pelvic surgery preventing this port or large inguinoscrotal hernia or sliding hernia the initial incision can be taken laterally to the midline on the contralateral side.

In bilateral hernias, the initial incision for entry of the camera and the tunnelling may be on either the left or the right of the midline. Hence in e-TEP, the initial umbilical placement of the trocar is adaptable to the case.



The initial incision is extended to the anterior rectus sheath which is incised for a little less than 1 cm. The muscles of the rectus can be identified, separated by the straight hemostats. The posterior rectus sheath is seen and identified.

A 10 mm trocar with a blunt tip is introduced to meet the posterior rectus sheath at a vertical angle, then turned horizontally and pushed for a short distance of a few mm. The blunt introducer is removed, 0-degree telescope is introduced, and the loose avascular plane of retro rectus area is identified. CO<sub>2</sub> insufflation is commenced at 12 -14 mm pressure of mercury. The to and from movements of the telescope tunnelling is made. The sheath of the trocar is advanced till it reached the lower border of the posterior rectus sheath. This method is used by the authors. This method is convenient and uses only the usual metal trocars available in every theatre, with no chances of entry into the peritoneal cavity. No stay sutures are required to hold the trocar in place which is snugly fitted to the site.

As an alternative, a balloon trocar can be introduced where the balloon is insufflated under vision in the retro rectus plane. Another method involves the usage of a transparent plastic trocar, which can be inserted into the retro-rectus plane similarly. The anchoring sutures may have to be used to retain the cannula in place.

The surgeon stands on the opposite side of the hernia with the nurse and the camera person.

Accessory 2 more ports are required. Their sites are also flexible. In single hernias, one accessory port can be umbilical and the other high in the lower abdomen on the contra-lateral side. On the other hand, the alternate port sites for accessory ports are one lateral to the umbilicus and the next lateral and lower to the first accessory port. Both the placements as above are ergonomic and allow for easy triangulation and suturing if necessary.

Division of the lower end of the posterior rectus sheath called Douglas's line is easy where the posterior fascial is too low and mars the view for dissection. The division of the inferior line of the posterior is fascia is done laterally to avoid a cut in the peritoneum. This cut widens the view and easy dissection of the tissues.



If there is an inadvertent pneumoperitoneum, the effect is minimal and the view remains good with such a large space. In this fashion, too e-TEP scores over TEP and surgery continue as planned. The rest of the operation and the mesh placement is similar to the TEP hernia. A larger mesh can be placed here as the space is larger and this too is an advantage.

Following the mesh deployment adequately, a controlled deflation keeping the mesh be it unfixed or fixed with sutures/tacks/ glue is carried out. Closure of the anterior rectus fascia is followed by subcuticular sutures.

### **Conclusion:**

e-TEP is easier to learn, easier to teach and easier in large hernias and more surgeons adopt them earlier than conventional TEP hernias. Management of distal sacs to avoid seroma is also easy in e-TEP hernia repair (3)

### **References:**

- 1) Daes J. The enhanced view- a totally extraperitoneal technique for repair of inguinal hernia. Surg Endosc. 2012;26:1187–88.
- 2) Jorge Daes. The eTEP technique for Inguinal Hernia Repair. Hernia Surgery. 2016; 467- 472.
- 3) Daes J. Endoscopic repair of large inguinoscrotal hernias: management of the distal sac to avoid seroma formation. Hernia. 2014;18:119–22.

## **Chapter 10: LAPAROSCOPIC REPAIR OF VENTRAL HERNIA**

- Introduction
- Incidence
- History
- Indications
- Contra indications
- Preoperative Preparation
- Operative Technique
- Position of Team
- Adhesiolysis
- Definition of Hernial Outline
- Sizing for the mesh
- Mesh Deployment IPOM & IPOM PLUS
- Primary Repair
- Primary Repair and Mesh
- Types of Mesh
- Types of Fixation of Mesh

### **Introduction:**

The term ventral hernia includes the broad spectrum of incisional, umbilical, epigastric or Spigelian hernias. 80% of all ventral hernias are due to incisional hernias. After laparotomy, predisposing factors for incisional hernia include sepsis, obesity, multiparity with the lax abdominal wall, prostatism in men, wound infection, chemotherapy and aneurysmal disease. Medical disorders contributing to rupture of the scar include jaundice, advanced cancer, renal failure, malnutrition and steroids.

## **Incidence:**

Incisional hernia incidence is high within 5 years of the original operation. Traditionally ventral hernias were repaired primarily by a laparotomy and direct suture technique, but these had a recurrent rate of 41- 52%. Herniorrhaphy with the strengthening of the wound with a prosthetic mesh was introduced in the 1960s. This operation consists of primary repair of the defect with sutures after the dissection of wide areas of soft tissues and placement of a prosthetic mesh. As the operation involved extensive dissection, this led to an increase in wound infections and wound complication to > 12%.

## **History:**

Since the first reported laparoscopic ventral hernia repair in 1992, minimal access surgery has grown in popularity with the advantages of shortened hospital days, early recovery and return to work, less pain and possibly fewer complications after surgery compared to open operation. Dr R Scott in a 2000 meeting of in America College of Surgeons during a discussion of a laparoscopic ventral hernia series presentation that the present study supported the assertion that laparoscopic surgery was the treatment of choice for ventral hernias. Laparoscopic techniques repairs are based on the Rives Stoppa open operation in which the plane between the rectus muscle and the posterior fascia is dissected widely. Mesh is then fixed to healthy abdominal wall fascia using full thickness. Though different methods of laparoscopic hernia repair are described below, most techniques include these principles but differ in the fact that the mesh is placed in abdominal cavity instead of being placed anterior to the fascia. Laparoscopic ventral hernia repair (LVHR) has gained popularity due to the incidence of shorter hospital stay, improve outcomes and fewer complications than open procedures, all of which have been proved to be true by several comparative studies.

This chapter describes the indications, techniques, and complications of laparoscopic hernia since 1992. This is followed by a discussion of various meshes available as well as the options of fixation of the mesh to the abdominal wall.

### **Indications:**

Most ventral hernias are amenable to laparoscopic treatment. Tension-free repair is the order of the day. Any ventral hernia operated by open technique may be amenable to laparoscopic technique also. The first-time ventral hernias may be easier for the inexperienced operator. If there is evidence of a large ventral hernia with previous meshes which had failed where there are multiple dense adhesions will be taxing even for the most experienced. Even in open surgeries, these would be demanding conditions for the surgeon.

### **Contra indications:**

Contra indications for tension-free mesh repair of ventral hernia include those in children and those unfit for general anesthesia due to severe respiratory or cardiac diseases. The inexperience of the surgeon is a limiting factor to the choice of hernias by laparoscopy. Presence of active infection limits the use of non-absorbable mesh. Use of absorbable mesh can be undertaken on selected cases knowing that these hernias would recur and they need repair at an elective time later on after the infections subside. In the presence of infection, an alternate solution might be the primary closure of the hernia would by laparoscopic technique provided the defect is small without the need for mesh.

### **Preoperative Preparation:**

Counseling of the patient includes a discussion of mesh insertion, need for multiple stab incisions to include the sutures, seromas after surgery and the fact the excess adiposity of the abdominal wall is not to be removed as part of the operation. In previously operated cases, it is wise to mention inadvertent enterotomies during dissection, and indications for conversion to open operation.

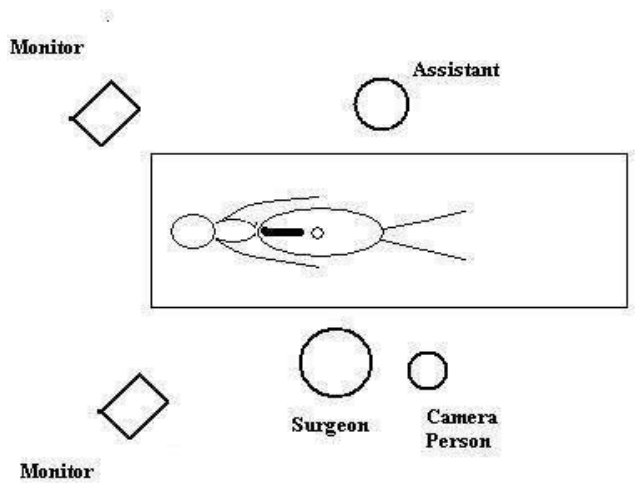
History includes prostatism, ruling out malignancies in the elderly as other causes of abdominal pain, asthma and chronic obstructive airway diseases. CT scan of the abdomen is indicated in the relevant cases. Naso gastric catheter and urinary catheter may be used as necessary.

## Operative Technique OF Laparoscopic Ventral Hernia Repair (LVHR):

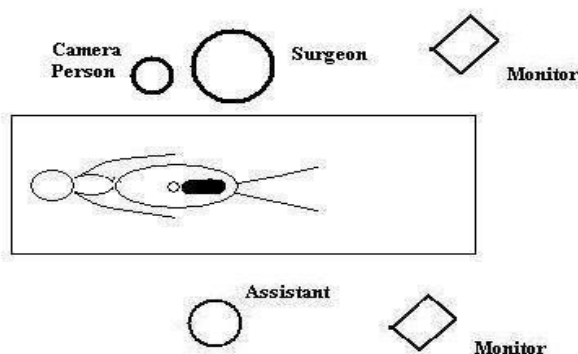
Initial set up:

The patient has endo tracheal intubation and general anesthesia. The patient is kept supine with both arms by the sides. For the lower abdominal hernias, urinary catheter is necessary and for the upper abdominal incisions, nasogastric catheter is required to keep the stomach empty. At the start of anesthesia, in intra venous cephalosporin is given and repeated over the first 24 hours.

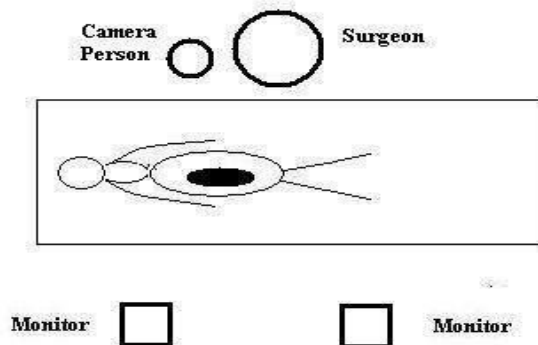
### **Position of Team:**



**Position of Team for Incisional Hernia Upper Abdomen**



**Position of Team for Lower Abdominal Ventral Hernia**



**Position of Team for Lower Abdominal Ventral Hernia**

For lower abdominal ventral hernia, the surgeon (right-handed) stands on the left side of the abdomen with camera person behind him; the monitors are placed near the lower end of the patient.

For the upper abdominal hernia, the right handed surgeon stands on the right of the patient with camera person to his right; the monitors are placed at the shoulders of the patient to enable the entire team to see the screens.

For umbilical incision the right handed surgeon stands on usually the left of the patient with the camera person to his back looking over his shoulder; the monitors are placed on the right of the patient. There should be place for the operating to move around during the operation and change places. Fixation of the mesh often requires the surgeon to move around with the camera person.

Access to the abdominal wall is gained by the Veress needle; there are others who have advocated Hasson's cannula and optical trocars where one sees the cutting edge of the blade while advancing into the abdomen. Veress needle is often used in Palmer's point which is the midpoint of the left subcostal plane as adhesions are minimal here. A corresponding point on the right of the patient also is useful due to the paucity of intra-abdominal adhesions at this site.

With the pneumoperitoneum firmly established, the hernia is seen to stand out from exterior prominently. The edges of the hernia are marked out clearly on the skin with a marking pen. The primary trocar is inserted as far away from the edge of the hernia defect as possible for at least a distance of 7.5 cm from the edge of the palpable defect either laterally for the inferior border of the hernia. The initial entry for the first 10 mm trocar is usually made subumbilically for the epigastric and supra umbilical hernias. The sub-umbilical hernias require the initial entry with first trocar from above the level of the umbilicus. For the umbilical hernia, initial entry is made from the lateral side usually on the left for the right handed surgeon. 10 mm telescope is passed and the interior is visualized. Two 5 mm accessory trocars are made under vision on either side of the primary trocar at a distance of not less than 5 cm. In cases with dense intra-abdominal adhesions, the first 5 mm accessory trocar allows the adhesiolysis to be made near the proposed site of the second trocar which is then inserted under vision. Now the telescope is changed to 30 degrees for better visualization of the peritoneal cavity.

### **Adhesiolysis:**

Lysis of the contents of the omentum and the bowel can be taxing for the surgeon. Sharp dissection is done to separate the contents from the abdominal wall. Energy sources are deployed only for obvious vascularized adhesions. Bipolar diathermy or ultrasonic scalpel dissection is useful if the bowel forms part of adhesion and heat sources are required. Special care is taken to avoid usage of monopolar diathermy near the bowel to prevent delayed thermal injury.

The contents of the sac are reduced. The usual contents are the omentum and bowel. Omentum can be pulled by a grasper with the left hand and taken down with the right hand. Often Swiss cheese type of sac is present due to multiloculations of the sac. Dissection is aided by the left hand of the surgeon which applies pressure from the exterior of the abdominal wall inverting the sac into the peritoneal cavity for better visualization at the time of reduction of the contents. Dissection extends for a distance of at least 4cm all around the margin of the defect.

### **Definition of Hernial Outline:**

The edges of the hernial orifice must be clearly seen as well as a distance of at least 4 cm all around it. Shape of the hernial orifice is usually circular or ovoid. The defect is measured by several ways. CO<sub>2</sub> can be let out, the abdomen is deflated the by palpation the hernial orifice is made out and marked and measured. With CO<sub>2</sub> pneumo peritoneum reestablished, needles inserted at the edges of the orifice give the correct reading of the hernial orifice.

### **Sizing the mesh:**

It is easier however to use a laparoscopic instrument inside the abdomen to measure by making the edges of the same against the defect. The instrument is then removed and measured against a sterile measuring scale. The mesh deployed should be at least 4 cm all around the mesh. A further distance of 8 cm is added to the largest diameter of the hernial defect gives the size of the mesh. If the largest diameter of the defect is for instance 5 cm, the length of the mesh would be calculated to be  $- D + 8$  where D is the diameter that is,  $5 + 8 = 13$  cm.

### **Mesh Deployment:**

An appropriate mesh is chosen and cut. 4 sutures are taken at the four corners usually with 2-0 prolene and cut long at both ends. The mesh is then rolled like a cigarette and passed via a large port into the abdomen. It is unrolled and laid open under the hernial defect over the abdominal viscera.

Multiple stab incisions are made on the skin with 15 blade knife at the four corners of the incisions marked out earlier. A suture passer or a port closure device is passed through the stab site to enter the peritoneal cavity. Each edge of the corresponding thread is grabbed and delivered to the exterior separately keeping a distance of at least 1 cm from each using the same stab site. This ensures that the ends of the thread traverse for a distance of 1 cm of tissues of the abdominal wall before they are tied up to ensure that they do not cut through the tissues. The edges of the thread are help up with hemostats keeping the mesh held firmly against the abdominal wall against the hernia orifice. The ends are left untied at this point to help adjustments to the mesh to prevent wrinkling or kinking of the mesh.



The optimum conditions for the mesh placement are:

- Mesh covers the entire orifice and extends for a distance of 4 cm all around the edges of the hernial orifice
- Mesh must be held taut with no wrinkles
- Fixation of the mesh all around is required. Fixation techniques are required all around the visible edges of the mesh and the abdominal wall for large meshes at an interval of at least 3-5 cm from each other.
- For small defects the stitches at the four corners of the mesh may suffice
- Large defects may require more frequent fixing techniques to ensure that the repair is adequate and to prevent herniation of the contents.

The edges of the sutures are held up with hemostats and are tied to keep the knots in the subcutaneous plane. No drains are required at the end of the operation. Skin incisions are closed after ensuring adequate fascial closure of 10 mm trocar site.

Methods of fixation of the mesh to the parties include the passage of suture passer, tackers or intra corporeal sutures . The passage of the special needle o the port closure device needs stab incisions and the introduction of the suture which is retrieved by another stab one cm away using the same stab incision. Depth of the suture is 1 cm and the knot is tied in the subcutaneous plane. endoscopic hernia staples – Autosutures, Ethicon or Origin tackers make the fixation of the mesh easy. Depth of fixation is 3-7 mm. Intra corporeal sutures can be done with no 1 prolene suture using a cutting needle with 1 ½ diameter . The mesh is held by 4 anchor sutures at the edge, kept taught and by an external finger indenting the edge of the mesh, non-dominant hand, the suture is taken using intra corporeal technique. Intra corporeal sutures or hernia staples or anchoring sutures are taken at a distance of 1.5 to 3 cm from each other at the perimeter of the mesh. The bigger the hernia, closer the sutures .

The other practised laparoscopic methods are:

- Primary Repair
- Single layer mesh reinforced by primary repair known as IPOM PLUS intra-peritoneal outlay mesh

### **Primary Repair:**

It may be considered in a young woman with symptomatic or incarcerated umbilical hernia with a previous history of caesarian section who wishes to have more children.

Where the defect is small, simple primary closure was considered possible. This technique involves the insertion of a laparoscope, adhesiolysis, measuring the hernial margin to ensure a diameter of less than 3 cm. Stab incisions are made along the edges of the margin and using suture passer or port closure needle interrupted prolene sutures were deployed passing at least 1 cm from edge of the hernia orifice. Distance between 2 sutures must not be more than 1 cm. These are tied at the end after minimizing the pneumo peritoneum and the knots are placed subcutaneously.

Recurrence rate is reported to be 50% with the primary closure.

### **Primary Closure with single Layered Mesh IPOM PLUS:**

This method is employed for incisional hernias with a diameter of less than 5 cm where a primary approximation of the edges is possible. An inlay mesh is deployed similar to LVHR after the primary repair.

A telescope is passed into the peritoneal cavity, lysis of adhesions. The edges of the hernial orifices are defined and measured.

Using a site 2 cm from the edge of the incision, a cutting 45 mm ½ circle needle issued to enter from the exterior of the abdomen without altering the curvature of the needle. The end of the thread is held in the exterior by a hemostat. The needle is retrieved from inside the abdomen and is used to suture the edges of the defect with a margin of at least 1 cm from the edges keeping the distance between 2 sutures not more than 1cm. Suturing is initiated from distal to proximal towards the telescopic end of the operator. At the end of this layer, the extra corporeal thread about 6 cm long is retrieved into the abdomen and ethanol is pulled at both ends thus approximating the edges of the wound. The continuous suture is doubled back away from the telescopic end towards the tail of the suture and these are tied together .

Now a method similar to LVHR is done using a mesh of approximate size. The four corners are marked with long prolene sutures. These are marked on the skin as well. Mesh is introduced intracorporeally.

Using stab incisions at the four corners, the 2 ends of the prolene are retrieved at each corner keeping a distance of 1 cm from them. The mesh is held taut and tied without wrinkles. The edges of the mesh are sutured intracorporeally with the same initial needle with no 1 nylon, making sure that adequate bites are taken of the abdominal wall. After ensuring adequate hemostasis and adequate approximation of the mesh to the parietes, the abdomen is deflated with no drains.

### **Types of Mesh:**

Dual meshes are the standard of care. Prolene were historically used long ago. These cause numerous bowel fistulas and hence are no longer used. Dual meshes have 2 or more coatings of absorbable material on the bowel side and non-absorbable material on the parietal side. The epithelium grew on the interior covering the entire mesh. These meshes are more expensive and should be used as per the manufacturer's instructions.

### **Types of Fixation of Mesh:**

1. For small hernial orifices, mesh with the sutures at the corners introduced intra-corporeally with long ties of non-absorbable material suffice. Mesh once introduced into the peritoneal cavity is suspended by bringing out the long ends at the corners with a distance of at least 1 cm from consecutive threads. Where ever indicated similar sutures can be taken in between the four sutures as well.

2. Centering of mesh may need to be done in large hernias to ensure 4 cm of mesh covers the margin on all sites. This may be done by laparoscopic visual judgement or by a centering stitch to the mesh before insertion. This stitch can be retrieved after insertion of the mesh from the exterior at the middle of the hernia.

3. The mesh covering the defect is adequately fixed with in additional staples or sutures. There are absorbable and non-absorbable staples. These save time and are much quicker to use. However, they are more expensive to use. Intra corporeal sutures consume more time and are less expensive.

4. Distance between 2 staples should be 1 to 1.5 cm and not larger as they form gaps encouraging bowel herniation. In large hernia defects, the double crowning technique is used where an inner layer of staples is used to ensure further strength.

## **Chapter 11: Ergonomics**

- Table Layout
- Ergonomics with reference to Suturing
- Position of Monitors
- Position of Surgeon/Camera person
- Position of ports
- Basics of Knotting and Suturing
- Purpose of Ergonomics
- Centering Target
- Azimuth Angle
- Manipulation Angle
- Elevation Angle
- Image distance
- Instrument Scope Alignment
- Extracorporeal Instrument Length
- Table Height
- Target Position
- Suture Line Alignment
- 3 D
- First Assistant
- HALS

### **Table Layout:**

If the room is of moderate size, the operation table can be in centre leaving enough space for surgeons, nurses and technicians to move around. If the room is small, then the table can be placed in the center, but obliquely so that there is enough space on all the four sides making it easy for everyone.

## Ergonomics with reference to the Basics of Suturing:

### 1. Purpose of Ergonomics

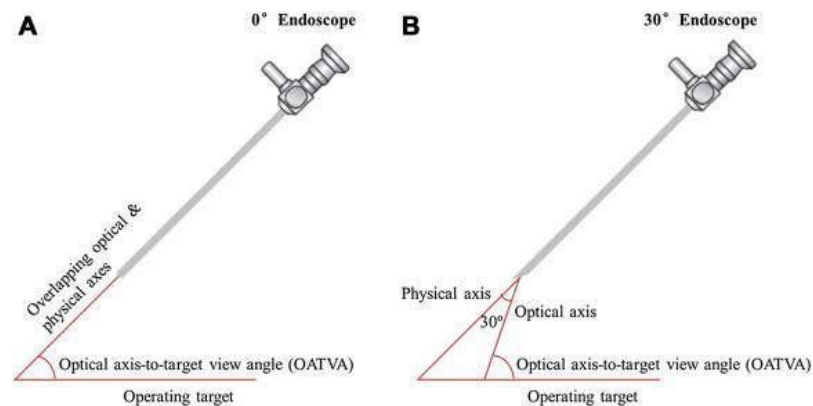
The purpose is to make the man-machine function optimal so that it is easy to operate without strain to the patient or the surgeon.

### 2. Center your target within your field of view.

### 3. Laparoscope orientation (Fig 1)

- Distal laparoscope lens should be parallel to target plane
- Laparoscope port placement differs with laparoscope angle
- Practically, change to laparoscope with a different angle rather than changing laparoscope than trocar position

(Fig 1)



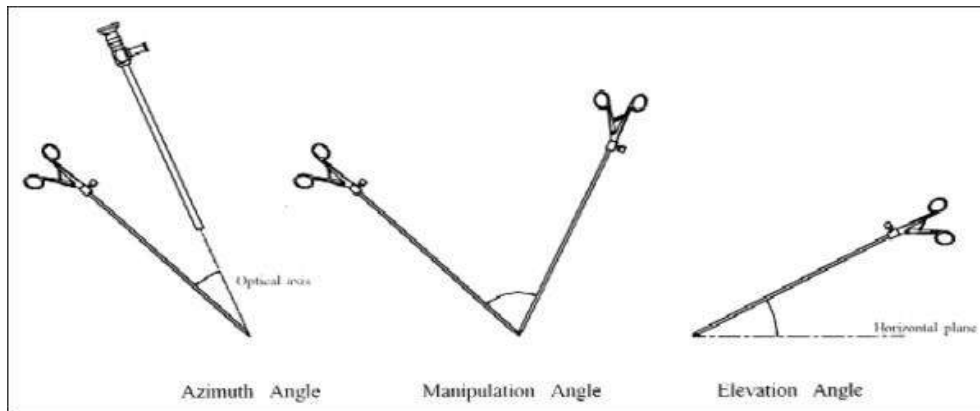
### 4. Target endoscope distance

- Best performance between 75 and 125 mm
- Less distance - Sword effect
- Excessive magnification - Reduced field of view

### 5. Azimuth angle is the axis of the instrument to the optical axis of the endoscope (Fig 2)

- 30 degree ideal
- Both instruments should be at equal azimuth angles
- Wider angles increase execution time

(Fig 2)



**6.** Manipulation angle is the Angle between the axis of two operating instruments (Fig 2)

- a. 60 degree ideal (45 degree – 60 degree)
- b. Ideal force and better work done
- c. Narrow angle – less force but more sword fighting
- d. Wider angle – more execution time

**7.** Elevation angle is the Angle between the target plane and instrument (Fig 2)

- a. 60 degree ideal (45 degree – 60 degree)
- b. More elevation – less force
- c. Narrow-angle – greater execution time

**8.** Image display

- i. Position of display from surgeon
  - (1) 4 X monitor size away from the surgeon
  - (2) Directly in front of the surgeon
- ii. Surgeon's eye to the monitor angle
  - (1) Minimum of 10 degree – 25 degree below surgeon's eye
  - (2) Best at surgeon's hand level
- iii. Surgeon, target and monitor axis
  - (1) Straight line
  - (2) Monitor should be tilted upward

**9.** Instrument and laparoscope alignment

a. Optimum alignment

- i. Instrument viewed from above
- ii. Best in front of the surgeon

b. Off axis alignment

- i. OK towards non-dominant hand
- ii. Dominant instrument to laparoscope (azimuth) angle of 30°
- iii. Reverse alignment is the Reversal of camera by 180°, degrading performance

**10.** Extracorporeal – Extracorporeal instrument length ratio ideally is equal or  $> 1$ , that is, keep more than half of the instrument shaft inside abdomen

- a.  $= / > 1$  Smaller hand movements create larger instrument tip movements
- b.  $< 1$  degrades task performance

**11.** Operative table height = Instrument handle between 0 and 10 cm below the elbow, raise or lower operating table or stand on stool as necessary

**12.** Target position

- a. Highest
- b. Mid-air in case of bowel

**13.** Suture Line Alignment

- a. Suture vertically, not horizontally
- b. Suture toward yourself

**14.** 2D vs. 3D—3D not better than 2D with currently available 3D systems

**15.** Laparoscopic first assistant

a. First assistant should have 2 port sites, so first assistant can use both hands

. Ergonomic set-up of the first assistant's instruments not completely possible, but should:

- i. Keep instrument tips at least 60° from the surgeon's instrument tips and from the first assistant's other instrument tip
- ii. Keep elevation angle (angle between instrument shaft and target tissue plane) ideally at 60° (45° – 60°)

b. Keep Intracorporeal – Extracorporeal instrument length ratio = or  $> 1$ , that is, keep more than half of instrument shaft inside the abdomen



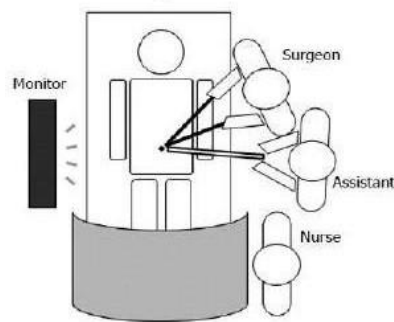
- i.  $\neq > 1$  Smaller hand movements create larger instrument tip movements
- ii.  $< 1$  degrades task performance
- c. Operative table height = Instrument handle between 0 and 10 cms below the elbow, stand on a stool if necessary (Fig 3)

(Fig 3)



- d. Use a separate monitor for first assistant
- e. Position of display from first assistant (Fig 4)
  - (1) 4 X monitor size away from the first assistant
  - (2) Directly in front of first assistant

(Fig 4)



- ii. First assistant's eye to the monitor angle
  - (1) Minimum of 10 degree – 25 degree below first assistant's eye
  - (2) Best at first assistant's hand level
- iii. First assistant, target and monitor axis
  - (1) Straight line
  - (2) Monitor should be tilted upward
- iv. Off-axis work, better on first assistant's non-dominant hand side of the laparoscope
- v. Avoid reverse axis work, that is, avoid instruments entering opposite laparoscope direction

## **16. HALS**

- a. Hand-access incision placement
  - i. Easy reach of internal hand to operating site
  - ii. Ability to extend wound during conversion
  - iii. Peripheral location or central location (transverse or midline)
- b. Frequent off-axis work
- c. Awkward lordotic positioning
- d. Decreased workspace – not ideal for small operating field

## Chapter 12: External Knotting

### **External Slip Knots:**

Extracorporeal slip knots are used to

- For interrupted knotting in difficult areas like in apposing crura of the diaphragm or deep in the pelvis
- Sutures which should be under tension as best tied with external knotting. More force can be applied than in intracorporeal knotting.
- Ligation of a major vessel or tubular structure like an enlarged cystic duct or a splenic artery.

Endoloops are preformed loops of knots already made commercially available in theatres and these are freely used to ligate the base of appendix in appendectomy. These can be applied easily using one trochar and are popular. They form part of external knots too. Once used, thread can be passed and external knot can be made using any of the techniques described below.

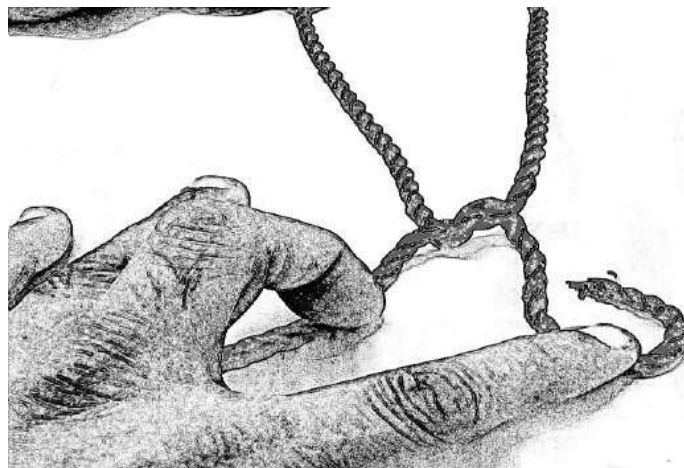
### **Making a Roeder Knot:**

This is the most popular knot which is used in endo-loops laparoscopic theatres for making external knotting as well as for endo-loops. These are commonly used for appendectomies. They can be taught easily to nurses and technicians apart from surgical trainees for their practice.

#### **Roeder Knot Step 1**

**Half a loop is created first by half knot. (Fig 1)**

(Fig 1)



**Roeder Knot Step 2:**

This is an ascending knot and is made upwards by making 3 turns upwards as in the fig 2.

(Fig 2)



**Roeder Knot Step 3:**

The tail is then reversed backwards in a half loop and the knot is made.(Fig 3)

(Fig 3)



### **Roeder Knot Step 4:**

The whole Roeder complex is then tightened and pushed upwards and does not come back making it a simple and ideal knot in end loops.(Fig 4)

(Fig 4)



### **Making a Tayside Knot:**

#### **Tayside Knot Step 1:**

This is a knot that can be used as an external knot to be pushed in by a knot pusher or as part of an end loop. Step one consists of an initial overhand knot.(Fig 5)

(Fig 5)



**Tayside Knot Step 2: (Fig 6)**  
**Four half turns are placed as in the Fig 6**

(Fig 6)



**Tayside Knot Step 3:**

The end is passed backwards to create a third loop.(Fig 7)

(Fig 7)



**Tayside Knot Step 4:**

The tail is pulled by reversing into the earlier loop . This is the end of knotting. (Fig 8)

(Fig 8)



**Tayside Knot Step 5:**

The entire loops are tightened. The whole Tayside knot slips forwards and not backwards and hence is an adequate knot to be used as an endloop for organs. (Fig 9)

(Fig 9)



## Chapter 13: INTRACORPOREAL (IC) SUTURING AND KNOTTING

Suturing skill is developed by practice and experience based on port placement, ergonomics and proper alignment with good triangulation. IC suturing catapults the surgeon to greater heights enabling him to do a wider choice of procedures such as hepatico jejunostomy, pancreatectomies with total IC reconstructions with suturing.

There are four steps on the way to achieving mastery of suturing in surgery. They are:

- Unconscious incompetence
- Conscious incompetence
- Conscious competence and ultimately
- Unconscious competence

Intracorporeal Suturing (IC) is used for tissue approximation. It is perfected by repeated practice on the endo trainer as well as in surgery. A variety of devices are used in standard laparoscopy to achieve IC suturing. Though ski needle was used earlier, most surgeons now use the standard curved needles for the material. The hand instruments can vary from surgeon to surgeon. Curved or straight tipped needle holders of the standard length are generally used with either a pistol-whipped handle or a motor bike handle type of grip. (Fig 1)

(Fig 1)






Needle entry into the abdomen is generally done by holding the thread beyond the needle and passing the same via the port or a reducer.( Fig 2)

(Fig 2)




Large needles can be introduced in thin patients by direct entry from outside or via a removed 5 mm port which is inserted with the holder holding the thread with the needle in the 5 mm trochar.(Fig 3)

(Fig 3)



Needle is held at the tip just as in open surgery of the needle holder generally at 90-degree angle. The tip of the needle enters the tissues at an angle of 90 degrees and makes a curve to exit. At exit, the needle is held with the non-dominant (left) hand, the tissues pushed back with the right hand. The needle is gently removed following the curve of the suturing with minimal damage to the tissues.

(Fig 4)



Grasping the needle can be achieved in the following ways. Needle is grasped at the 'sweet spot' at junction between proximal and middle 1/3 of the needle. (Fig 4)

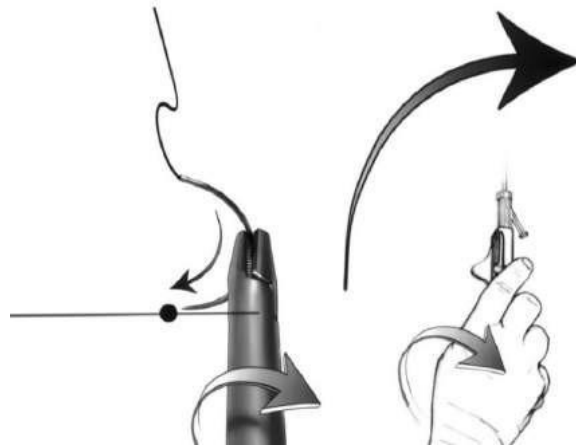
One is to grasp the suture tail above the needle and let the needle hand over the tissues so that the right handed needle holder can grasp the appropriately directed needle. The second method is to place the needle in the correct alignment on the tissues and grasp it with the needle holder at the right angle.

Yet another way is to hold the needle with the left hand and pass it to the right hand. When done in the air, this is clumsy; the method is better and quicker if the needle is held down on the tissues at the time of passing on to the right hand.

## **TECHNIQUE OF INTRACORPOREAL(IC) SUTURING:**

- Camera ports should be between the ports used for suturing so that the triangulation is ideal.
- Arms should rest below and elbows at 90 degrees or less to prevent fatigue.
- Site of suturing should lie vertically.
- While suturing, there should be no wasted movements of hands. There should be a choreography of practiced movements.
- One-half of the laparoscopic instrument length should be in the port to create a fulcrum. The surgeon should have the instrument directly in front of him with camera at 90 degrees for the triangulation.
- The needle should be locked at right angles to the needle holder with curved needles.
- Rotation at the forearm is preferable to abduction at the elbow to obtain adequate tissue with the needle.
- When the needle is inserted in the tissue, rotation at wrist is preferable to achieve a satisfactory curved passage of the needle without any laceration. (Fig 5)

(Fig 5)



- The site being sutured should be in line between surgeon and the monitor; it is ideally seen at upper part of monitor and hence the table may need to be tilted upwards

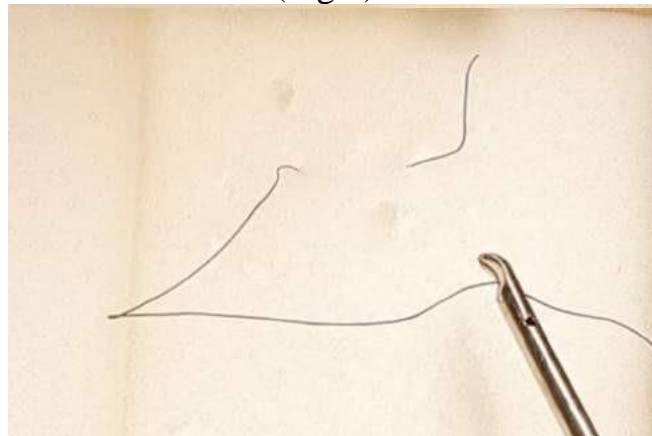
- Ideal length of intra-corporeal suture for interrupted bites is 15 cm. In some areas such as funduplications where a large amount of tissues are used, the length has to be considerably longer. For tying knots, short lengths of thread are ideal.
- Extracorporeal sutures require long threads such as 27 to 36 inches or longer like in Roeder or Tayside knots.

### **INTRACORPOREAL (IC) KNOT TYING:**

Intracorporeal knotting has to be practised on endo trainers and performed at live surgery. The steps can be described to make the performance easier and choreographed to make it look professional.


The needle is inserted through the tissue to be sutured. It should be removed by the left or the right hand using a wrist rotation following the curve of the needle, till 1 to 2 cm of the tail is left visible. (Fig 6)

(Fig 6)



The curves of the needle holder on the right hand and the grasper on the left hand should face each other and the left-hand makes counterclockwise under the suture while the right hand rotates clockwise making the first loop (Fig 7).


(Fig 7)



The first half of the knot is made and it is laid flat and taut so that the tail is easy to grasp during the next half.

The left-hand grasper holds the thread below the level of the needle to form a C loop. The right-handed needle holder moves clockwise through the loop and grasps the tail making the second half of the knot.(Fig 8)

(Fig 8)

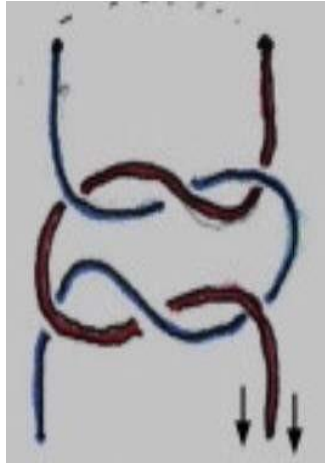


Thus the reef or square knot is made.

Both knots are made in opposite directions and hence they make a square or reef knot. If they are made in the same direction, they make a granny knot.

**Fig 9 Granny Knot:**

(Fig 9)

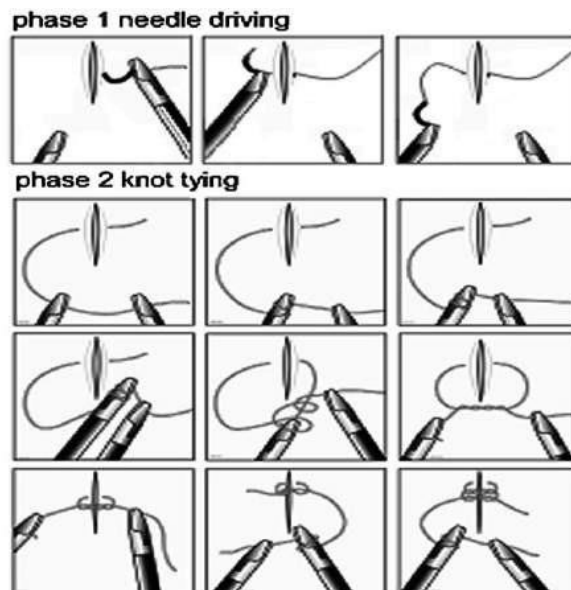


While tying the knots, equal tension is given at the end of the knotting equally from both hands so the knot remains without slipping.

**METHODS OF COMPLETING THE KNOTTING EFFICIENTLY:**

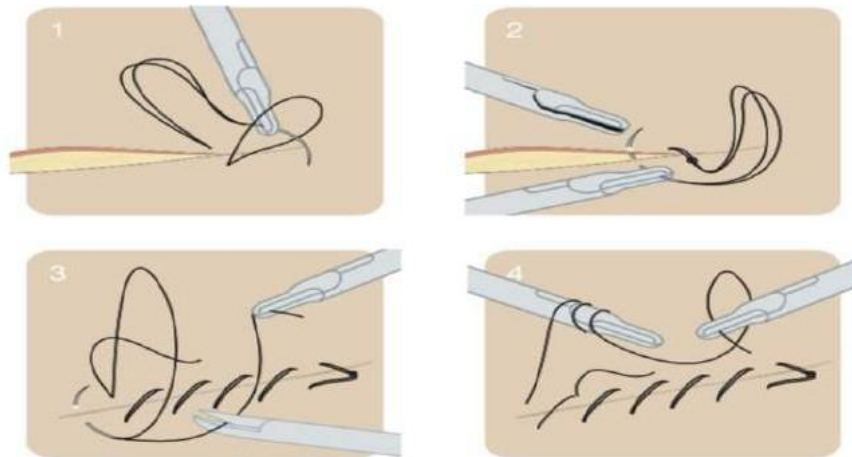
Method 1: Suture with the needle is transferred to the left grasper. The right grasper makes a clockwise movement and through the loop, grabs the tail. The graspers are pulled apart – the left grasper going to the left and the right going in the right direction and the knot is laid. Here the hands have to be exchanged. (Fig 10)

(Fig 10)



Method 2: Continuous suture with loop is also possible by the threading the needle through the sutures loops. The first suture fixation is done without knotting. (Fig 11).

(Fig 11)



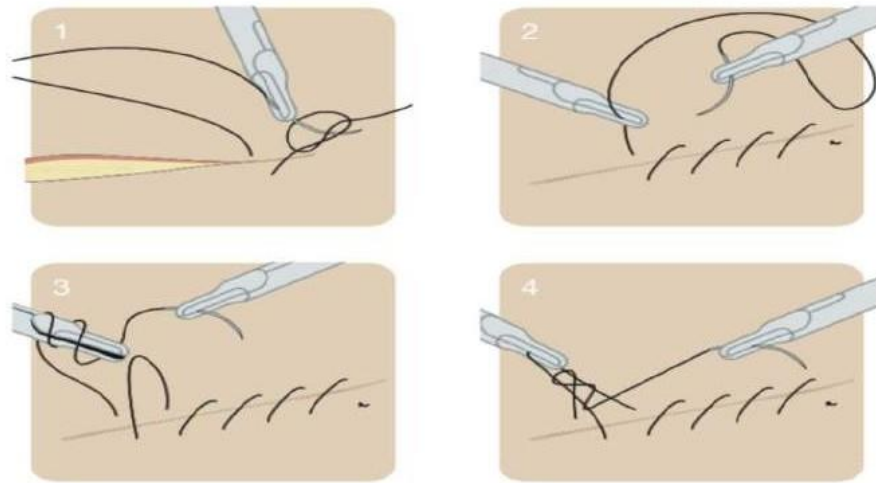
**Continuous suture with loop. By threading the needle through the suture loop the first suture fixation is created without knotting.**

This method is more efficient with lesser movements but involves the crossing of instruments. The needle side of the suture remains with the left hand and a C loop is made. The Left hand moved towards the tail with a clockwise motion while the right-handed grasper wraps the suture clockwise. At this point, the instruments are crossed and pulled apart to ensure a good lie of the knot.

Picture of knotting continuously

Figures 12 show how to keep the same hand on the thread while suturing. This forms the first half of the knot. The right-handed grasper continues holding the thread and makes a loop through which the left-handed instrument grabs the tail and makes the left side of the knot.

(Fig 12)

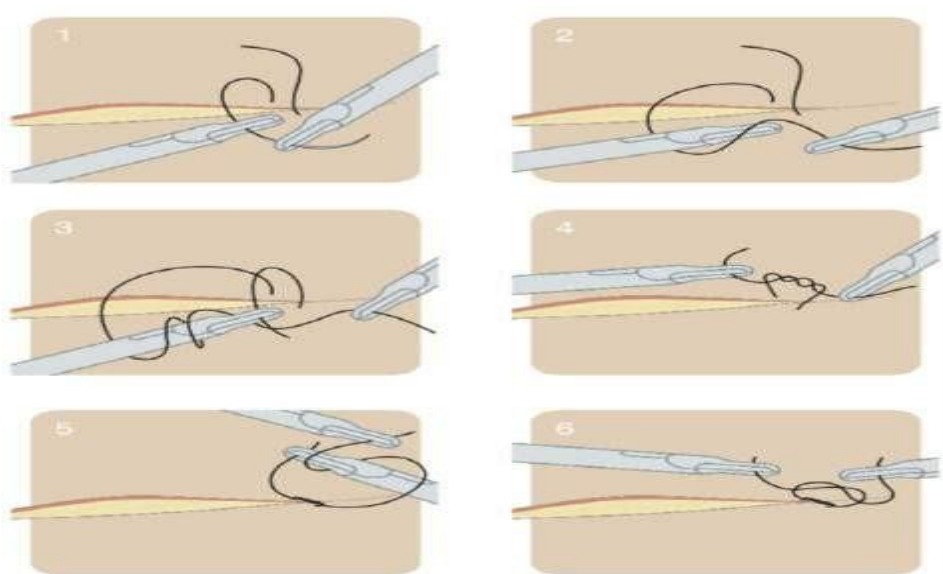


Continuous suture with pre-arranged first knot.

### **FINISHING A CONTINUOUS SUTURE:**

Method 1: While finishing a continuous suture, the last but one knot is locked. When the last stitch is made, a loop is left on the left side. The needle is then brought to the right side. Knotting is made between the needle side and the loop on the left as described. Figure 13 shows ending a continuous suture the usual way.

(Fig 13)

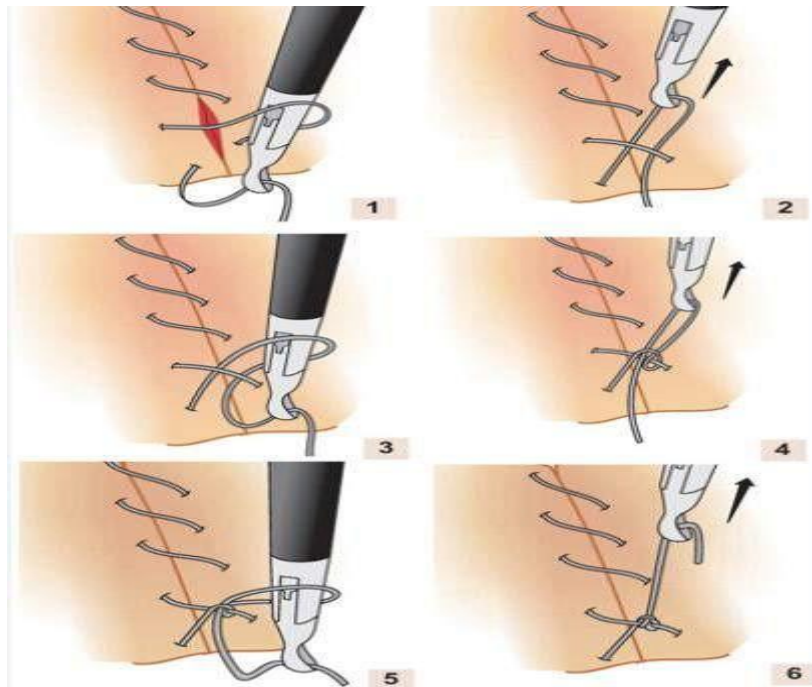




Picture showing the ending of the continuous suture.

Method 2: Aberdeen Knotting (Fig 14) is good when the end of the thread is short after a long suture suturing episode. It is easy to make; on the negative side, one cannot do a well-seated reef knot with it. The method of making an Aberdeen knot is to leave a loop on the left of the suture at the very end. The needle passes through the loop and grasps the thread close to the needle and pulls, making yet another loop (but the needle remains on the left out of the loop). Some tension is created to make a half knot. Thus the process is repeated many times. The needle is finally pulled through the loop and the Aberdeen knot is completed.

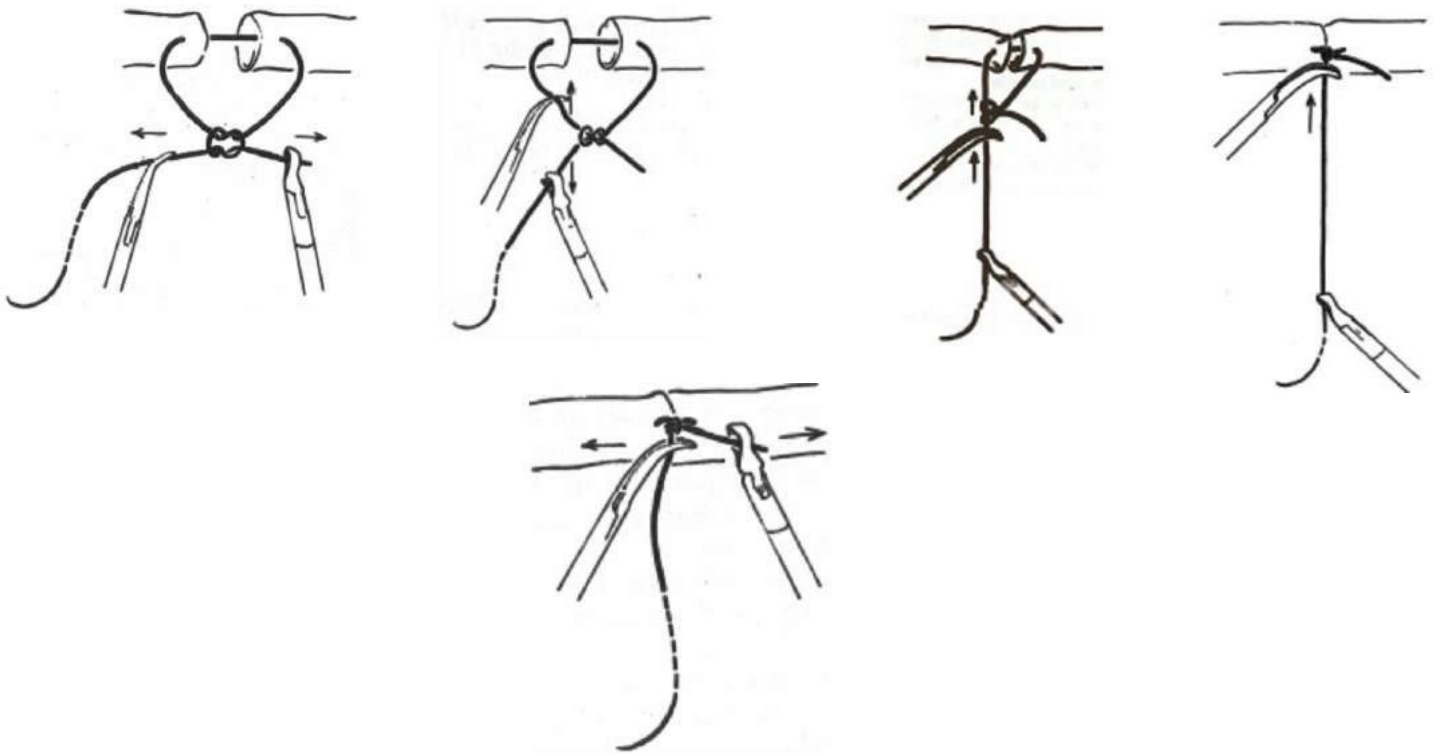
(Fig 14)



### **Sliding knot:**

If a knot has to be under some tension, a sliding knot may be used. The steps are to initially make a loose reef knot. Then pull the suture on the same side (such as on the left), straightening one side of the thread so that on the right side the knot will slip down tightening it. In the end, when pulled at right angles, the knot is well laid. (Fig 15)

(Fig 15)



**Fig. 15 Steps in creating a sliding knot**

### **SINGLE-HANDED KNOTTING:**

Knot tying in laparoscopic surgery traditionally involves the use of two instruments (for fashioning an intra-corporeal knot) or passing of a ligature around a tubular application structure, exteriorising it, fashioning a knot, and sliding it down with a knot-pusher (external slip knot).

With increasing interest in expanding applications of single-incision laparoscopic surgery (SILS), surgeons are faced with new challenges. Single-handed knotting is used using only one port. This can be applied from

a geometrically inconvenient port unlike in the rest of the standard laparoscopic knotting. Steps of single handed knotting (Fig 16-22) are described for practice in endo-drainer.

**(Fig 16) Steps include encircling the duct,**

(Fig 16)



Figure 1: Suture material being passed around the tube

**(Fig 17) Formation of 'O' with overwrapping**

(Fig 17)




Figure 2: Formation of an 'O'

**(Fig 18) Formation of first half knot**

(Fig 18)



Figure 3: Grasper carrying the suture through the 'O' to initiate the first half knot

**(Fig 19) Completion of first half knot**

(Fig 19)



Figure 4: The first half knot is tightened into position

**(Fig 20)Formation of second 'O' by under wrapping**

(Fig 20)



Figure 5: Formation of second 'O' by underwrapping.

**(Fig 21)Formation and completion of the second half of knotting**

(Fig 21)



Figure 6: End of the suture carried through the 'O'

**(Fig 22)Completed Single handed knotting.**

(Fig 22)



Figure 7: Completion of the knot by pulling the ends of the suture in opposite directions

**Single Incision Laparoscopic Suturing:**

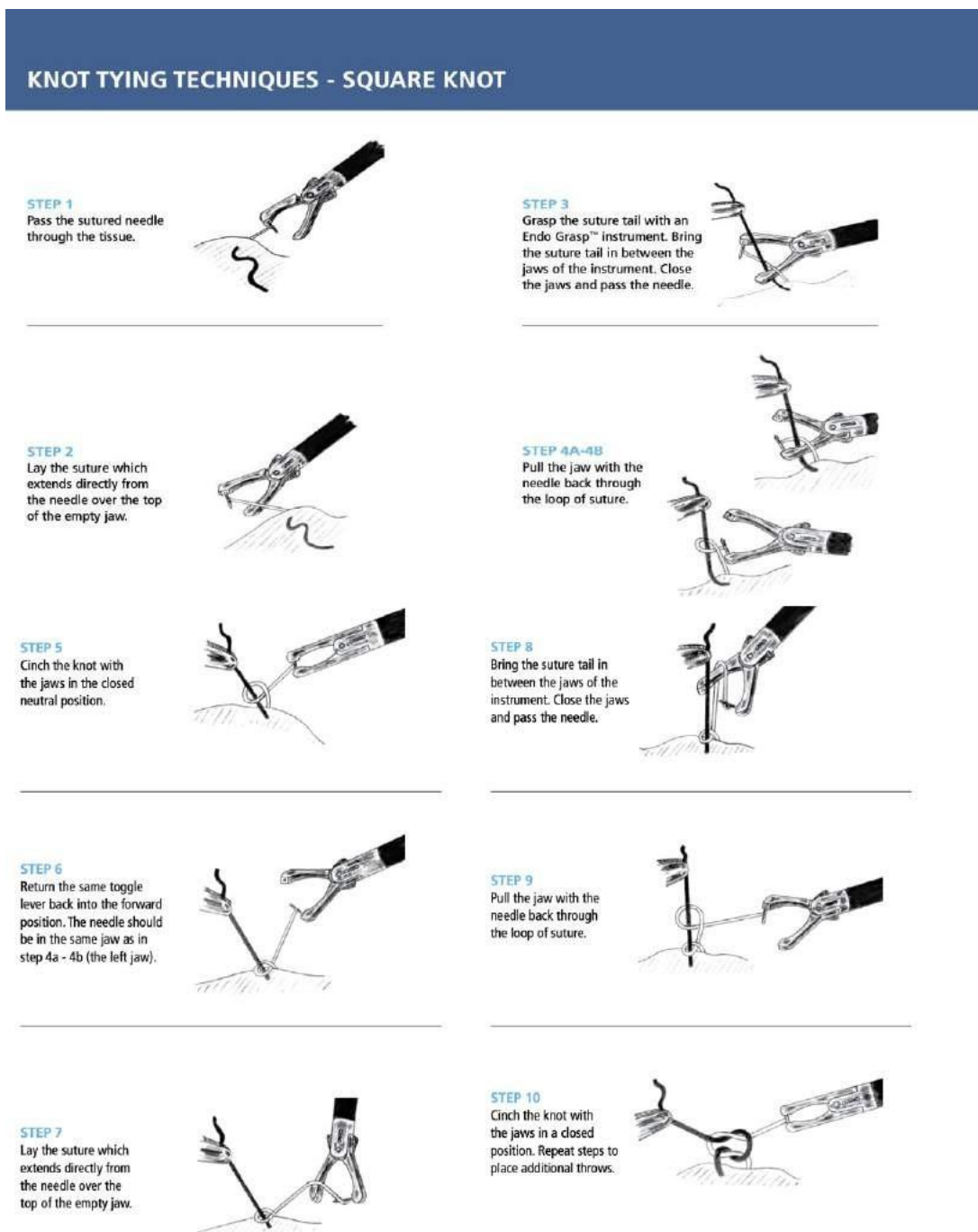
With single-incision laparoscopic surgery becoming more popular, there is an increasing need for surgeons to learn not only to knot but also suture in SILS. The ergonomics of suturing concerning ports, and angles of entry do not apply. The needle is passed directly via the abdominal wall or introduced via a reducer of the SILS port. Using a needle holder on one hand and the curved grasper, the suturing is carried out. The main difference in suturing is the knot tying and the suturing is done in a forward and backward movement rather than at the level of the wrist of the surgeon. Using Maryland curved forceps on the left (non-dominant hand) helps a great deal in knots at the end of suturing. If the thread is short then even a right-angled grasper is useful to negotiate the loops in the knotting. The camera person plays a special role in obtaining different angles to enable the surgeon to continue suturing and knotting and the role of a 30 or 45-degree telescope cannot be overemphasized.

## **SUTURING DEVICES:**

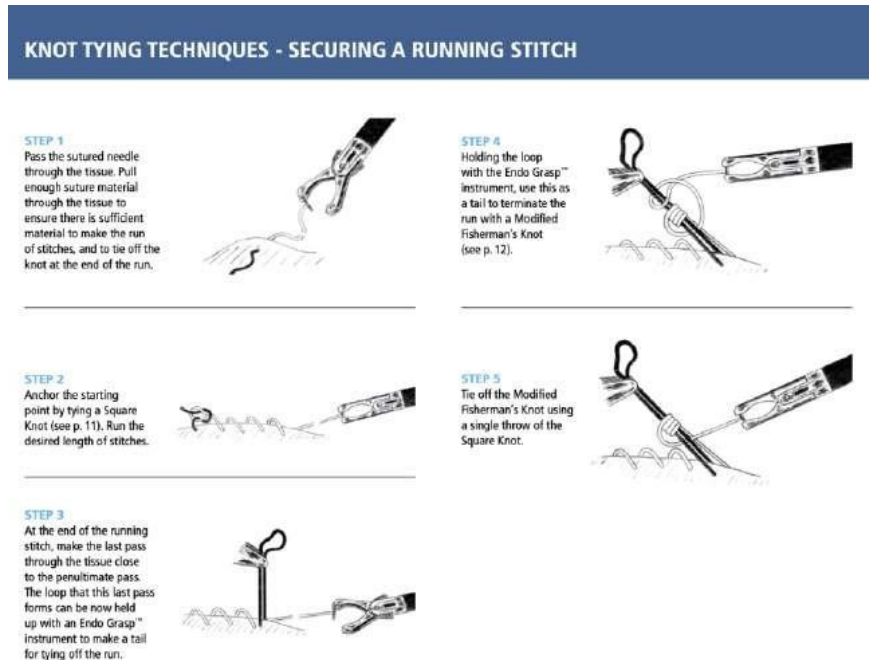
There are suturing devices available for making suturing easy. On the upside they make suturing faster with practice, needing very little assistance from anyone else. On the downside, fine suturing is not possible with them, they are expensive and they have to be available in the theatre.

Covidien endo stitch (Fig 23) is a popular suturing device with a long handle and a special small needle with two ends and a thread coming off the middle. It is a disposable 10 mm instrument used for interrupted and running stitches. (Fig 24)

(Fig 23)



(Fig 24)



Other suturing devices include Suture Assistant Knot Tying Device (Ethicon), Sew Right SR 5 and Ti-Knot TK-5 (LSI Solutions). These are all disposable devices with exchangeable cartridges.

Sutures with barbs (V-loc) are popular with hernia surgeons as no knotting is required (Fig 25). The initial stitch is passed through a built-in loop of the barbed suture. Pulling the suture through the tissues keeps it in place due to the barbs built into the suture. There is no need to tie knots. These are finding popularity among abdominal wall reconstructive surgeons and gynaecologists.

(Fig 25)





## **CHAPTER 14. COMPLICATIONS OF LAPAROSCOPIC SURGERY**

### **COMPLICATIONS OF LAPAROSCOPIC SURGERY**

Complications of laparoscopic surgery are broadly classified into the following groups

1. Access-related complications
2. Pneumoperitoneum-related complications and
3. Procedure-related complications

#### **1. Access-related complications:**

Access by the closed method of using a Veress needle is common all over the world. Nasogastric catheter is inserted to empty the stomach and a urinary catheter to empty the bladder. A stab incision below or at or above the umbilicus allows the Veress needle to enter the peritoneal cavity.

The position of the Veress needle in the peritoneal cavity is verified by a sucking-in noise at the onset. Correct position of Veress tip is confirmed by a drop test with saline where the saline is sucked in, followed by a free flow of saline from a syringe, verified by the absence of saline, bile or blood into the syringe by aspiration. CO<sub>2</sub> inflation inflates the abdomen equally in all 4 quadrants and thus pneumoperitoneum is verified.

The next method is the open-access technique. Using an incision as above, the cut is made from skin to peritoneum under direct vision. After ensuring no bowel adhesions all around, trocar is inserted under the vision and secured by either sutures or a Hasson cannula.

A third method is to use a transparent optical trocar guided by telescopic vision.

Complications due to access can be up to 5% of the cases (1). Previous surgical scars are not contraindications for laparoscopy but dictate the need for caution while planning access. Hematoma (2.0%), umbilical hernia (1.5%), and umbilical wound infection (1.2%) are all complications. The injuries due to access to viscera occurred in about 0.2% of cases. The open technique has no significant incidence of major vessel or bowel injury,

which can be dramatically seen in occasional cases of the closed type associated with Veress needle entry method.

In general, the surgeon should be conversant with all the methods of access and should predominantly use one method for common cases.

## **2. Pneumoperitoneum-related complications:**

Though laparoscopy offers many advantages to the patient, CO<sub>2</sub> pneumoperitoneum can cause respiratory acidosis as a result of absorption of the CO<sub>2</sub>. Deep venous thrombosis is higher with 40% in calf muscles and 15% in axillary veins. Cardiac output can be diminished by 30% with BP fluctuations. Patients with Cardiac-disease will do well with invasive cardiac monitoring during pneumoperitoneum. Preloading with fluids in supine rather than reversed Trendelenburg may be considered for these cases.

## **3. Procedure-related complications:**

### **Laparoscopic cholecystectomy**

After 3 decades of laparoscopic cholecystectomy, the most important complication of the operation is biliary injury. Major injury may occur with acutely inflamed gallbladders, pancreatitis, abnormal biliary anatomy (2) and experience of the surgeon (3). The overall rate of common bile duct injury was 0.31%, this rate significantly decreasing after experience with several operations performed. Misidentification of the common bile duct or the common hepatic duct for cystic duct forms the main mechanism of major injury (4). The next method of injury is thermal injury paving the way to delayed stricture of the biliary tree. The best repair is the first attempt at repair; the earlier the better. Repair should be carried out preferably by an experienced hepatobiliary surgeon.

### **Laparoscopic fundoplication**

Laparoscopy for anti-reflux correction has led to an increased incidence of these operations. Complications include perforation of the oesophagus or stomach, or splenic injuries resulting in the removal of the spleen and pneumothorax. The main advantage of laparoscopic funduplications is lower wound sepsis and cardiopulmonary complications. The hospital stay and the cost have decreased significantly (5). Dysphagia may occur in 22 - 57 %

with the need for dilatation in 4-32% of the cases. Mobilisation of the greater curvature of the stomach will allow a more floppy wrap around the oesophagus decreasing dysphagia (6,7). Lung complications include pneumonia and atelectasis of the lungs.

### **Laparoscopic inguinal hernia repair**

The Laparoscopic Transabdominal pre-peritoneal herniorrhaphy (TAPP) method of surgery for inguinal hernia involves entry into the peritoneal cavity, creation of preperitoneal space and placement of a large prolene mesh and closure of peritoneum over it to prevent intestinal fistulation. Complications occur during or after TAPP in 6-31% of cases (8 - 13). Apart from access-related injuries, others include injury to the urinary bladder, inferior epigastric vessels, the spermatic cord and seroma. Recurrence of inguinal hernia after surgery occurs as a complication in 1.0 - 2.9 % of cases. Mesh infection can occasionally occur related mainly to the sterilisation techniques of the equipment used. Port site hernia can occur uncommonly. Urinary retention can occur in 3-7% of cases. Post of neuralgia can also occur as a long-term complication.

### **Laparoscopic appendectomy**

While at open appendectomy the commonest complication was wound infection (14), the most common complication of laparoscopic appendectomy was an intra-abdominal abscess. Recent studies (15,16) may point to increased intra-abdominal sepsis in the laparoscopic group.

### **Laparoscopic colectomy**

Laparoscopic colectomy offers the advantages of less pain, less morbidity, less hospital stay and early return to normal activity after bowel resection surgery. While in full laparoscopic procedures, the entire resection and anastomosis are completed intra-corporeally, in assisted procedures, the dissection and ligation are carried out intra-corporeally while the bowel is delivered outside the body using a limited incision and the resection anastomosis is carried out exteriorly.

Complications during surgery include inadvertent enterotomy, bleeding from mesenteric vessels and ureteric damage. Conversion to open surgery, though not a complication of laparoscopy can occur 8 - 25% of the time. As the experience increases beyond 40 cases (17), the complication rate comes down.

## **Conclusion:**

The experience of the surgeon plays a vital role in the outcome of surgery. The magnified telescopic view is an advantage, though the decreased tactile feed back of feeling the tissues can be a disadvantage. The duration of surgery also decreases with more experience and the learning curve remains a reality in laparoscopic surgery.

## **References :**

- 1) Surgical Treatment: Evidence-Based and Problem-Oriented  
Holzheimer RG, Mannick JA, editors.  
Munich: [Zuckschwerdt](#); 2001.
- 2) Russell J C, Walsh S J, Mattie A S, Lynch J T. Bile Duct Injuries, 1989–1993. *Arch Surg.* (1996);131:382–388.
- 3) Moore M J, Bennet C L. The Southern Surgeons Club. The learning curve for laparoscopic cholecystectomy. *Am J Surg.* (1995);170:55–59. [[PubMed](#)]
- 4) Lee V S, Chari R S, Cucchiaro G, Meyers W C. Complications of laparoscopic cholecystectomy. *Am J Surg.* (1993);165:527–532. [[PubMed](#)]
- 5) Eshraghi N, Farahmand M, Soot S J, Rand-Luby L, Deveney C W, Sheppard B C. Comparison of outcomes of open versus laparoscopic Nissen fundoplication performed in a single practice. *Am J Surg.* (1998);175(5):371–374. [[PubMed](#)]
- 6) Leggett P L, Churchman-Winn R, Ahn C. Resolving gastroesophageal reflux. *Surg ends.* (1988); 12: 142-18.
- 7) Peters J H, DeMeester T R, Crookes P, Oberg S, de Vos Shoop M, Hagan J A, Bremner C G. The treatment of gastroesophageal reflux disease with laparoscopic Nissen fundoplication. *Ann Surg.* (1998);228(1):40–50. [[PMC free article](#)] [[PubMed](#)]
- 8) Voitk A. The learning curve in laparoscopic inguinal hernia repair for the community general surgeon. *Can J Surg.* (1998);41(6):446–450. [[PMC free article](#)] [[PubMed](#)]

- 9) Kiruparan P, Pettit S H. Prospective audit of 200 patients undergoing laparoscopic inguinal hernia repair with follow-up from 1 to 4 years. *J Royal Coll Surg Edinb.* (1998);43:13–16. [[PubMed](#)]
- 10) Leibl B J, Schmedt C G, Schwarz J, Daubler P, Kraft K, Schlossnickel B, Bittner R. A single institution's experience with transperitoneal laparoscopic hernia repair. *Am J Surg.* (1998);175(6):446–451. [[PubMed](#)]
- 11) Litwin D E M, Pham Q N, Oleniuk F H, Klufftinger A M, Rossi L. Laparoscopic groin hernia surgery: the TAPP procedure. *Can J Surg.* (1997);40(3):192–198. [[PMC free article](#)] [[PubMed](#)]
- 12) Wellwood J, Sculpher M J, Stoker D, Nicholls G J, Geddes C, Whitehead A, Singh R, Spiegelhalter D. Randomized controlled trial of laparoscopic versus open mesh repair for inguinal hernia: outcome and cost. *Br Med J.* (1998);317(7151):103–110. [[PMC free article](#)] [[PubMed](#)]
- 13) Zieren J, Zieren H U, Jacobi C A, Wenger F A, Muller J M. Prospective randomized study comparing laparoscopic and open tension-free inguinal hernia repair with Shouldice's operation. *Am J Surg.* (1998);175(4):330–333. [[PubMed](#)]
- 14) Slim K, Pezet D, Chipponi J. Laparoscopic or open appendectomy: a clinical review of randomized controlled trials. *Dis Colon & Rectum.* (1998);41(3):398–403. [[PubMed](#)]
- 15) Hellberg A, Rudberg C, Kullman E, Enochsson L, Fenyo G, Graffner H, Hallerback B, Johansson B, Anderberg B, Wenner J, Ringqvist I, Sorensen S. Prospective randomized multicentre study of laparoscopic versus open appendectomy. *Br J Surg.* (1999);86:48–53. [[PubMed](#)]
- 16) Kluiber R M, Hartsman B. Laparoscopic appendectomy: a comparison with open appendectomy. *Dis Colon & Rectum.* (1996);39(9):1008–1011. [[PubMed](#)]
- 17) Bennett C L, Stryker S J, Ferreira R M, Adams J, Beart R W. The learning curve for laparoscopic colorectal surgery: preliminary results from a prospective analysis of 1194 laparoscopic-assisted colectomies. *Arch Surg.* (1997);132(1):41–45. [[PubMed](#)]



## **Dr. Pradeep Chowbey**

MS, MNAMS, FRCS(London), FIMSA, FAIS, FICS,  
FACS, FIAGES, FALS, FAMS

I was pleased to learn about the Handbook on Laparoscopic surgery written by my colleague and friend Dr. John Thanakumar. I wish this handbook great success and popularity that it richly deserves.



## **Dr. S. Easwaramoorthy**

Prof of Surgery, Dept. of Surgery, Lotus hospital, Erode  
This 'Handbook of Laparoscopic surgery' has been well written with innumerable practical tips on various common topics in laparoscopic surgery.



## **Dr. Sathish Midha**

MS, FICS, FIAGES, EFIAGES, FAGIE, FAIS, FISG, FSGEI

I would like to thank and congratulate Dr Pravin John and Dr John Thanakumar for taking up this academic venture of compiling a treasure of knowledge which will be beneficial for many postgraduates, young and established surgeons.